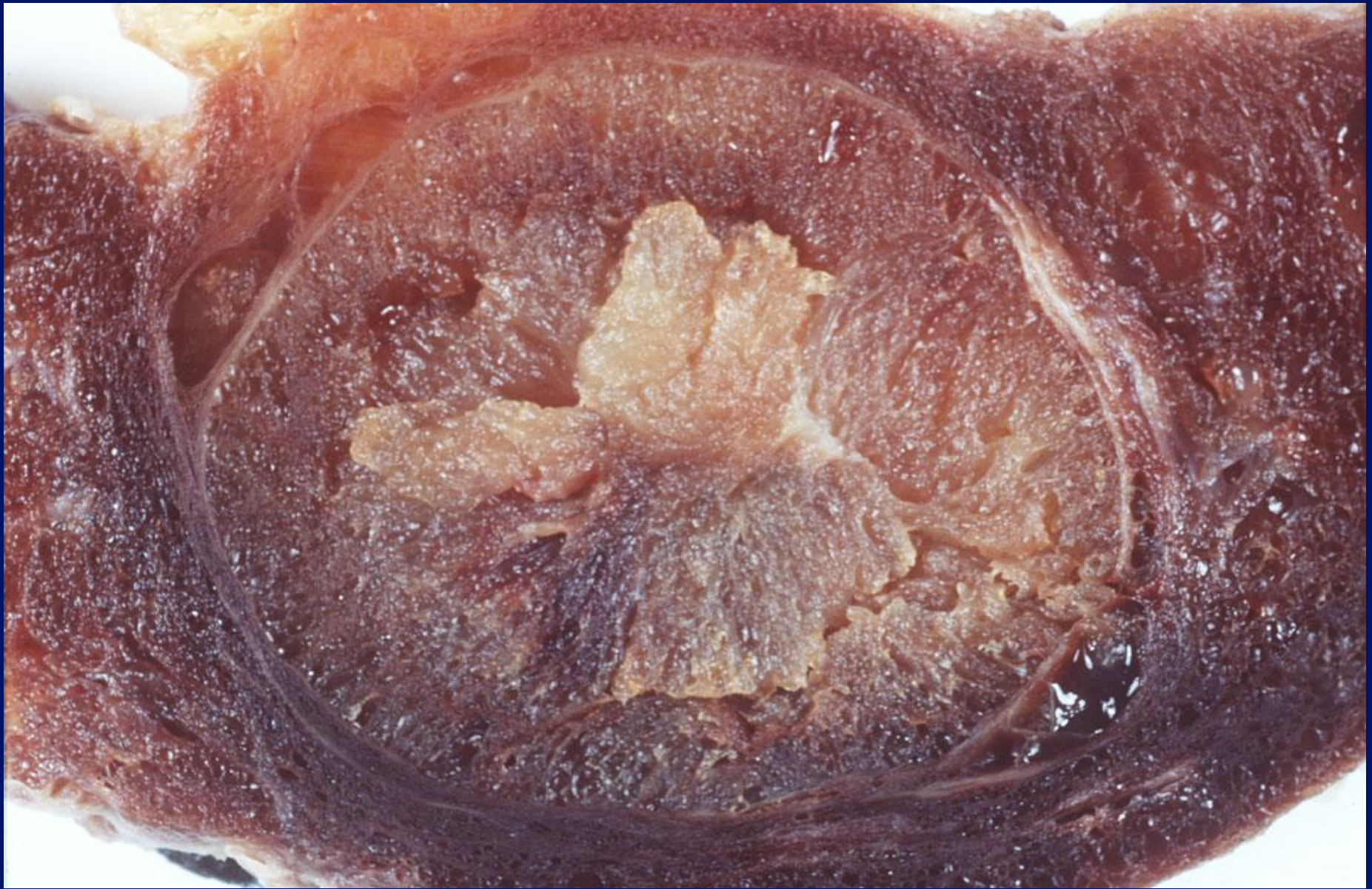


Thyroid & Parathyroid glands – Ultrasound evaluation.

www.headandneckultrasound.co.uk

Rhodri M Evans



Incidence

Thyroid Nodules

70

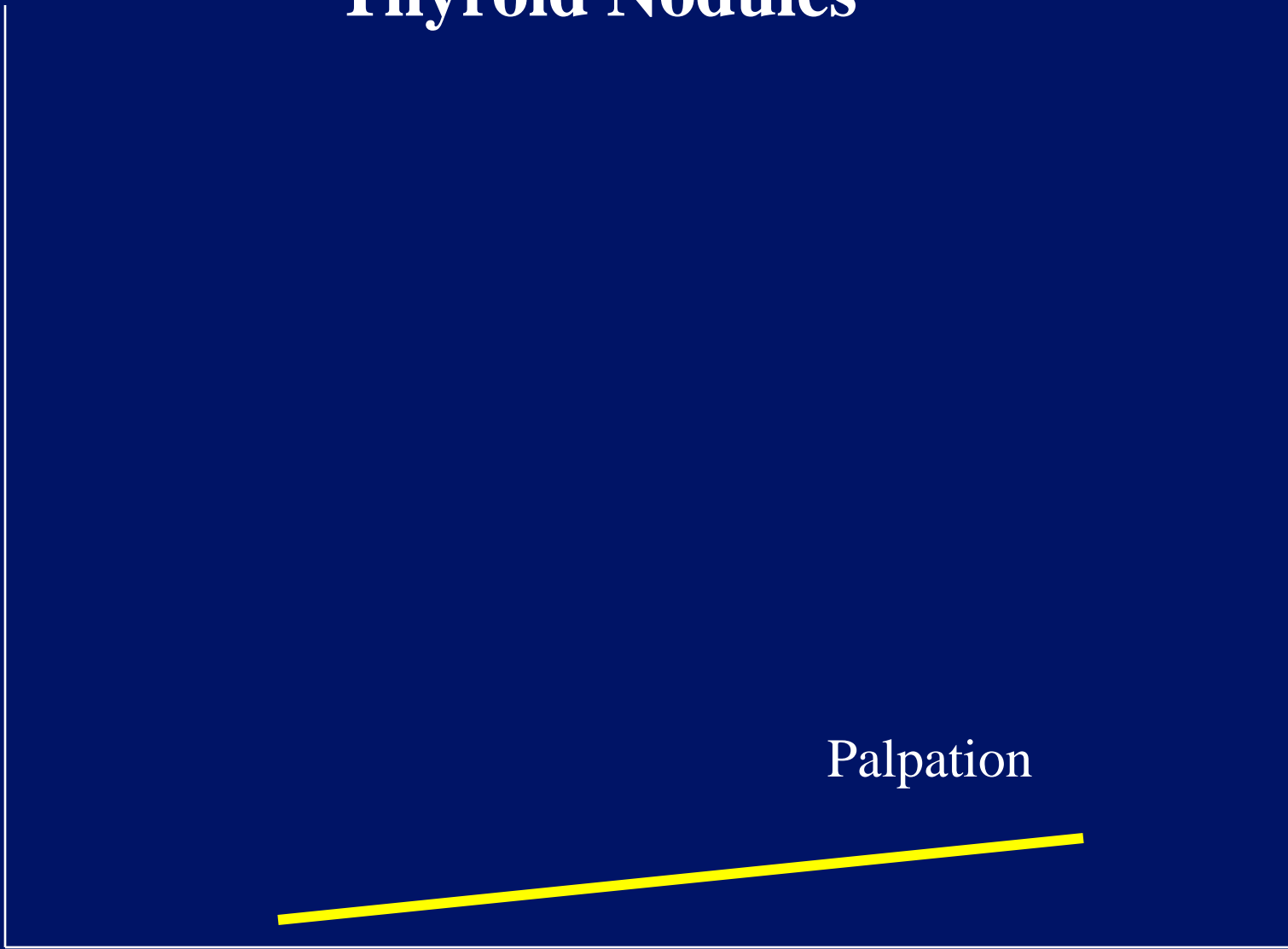
30

Palpation

50

Age

100



Incidence

Thyroid Nodules

70

30

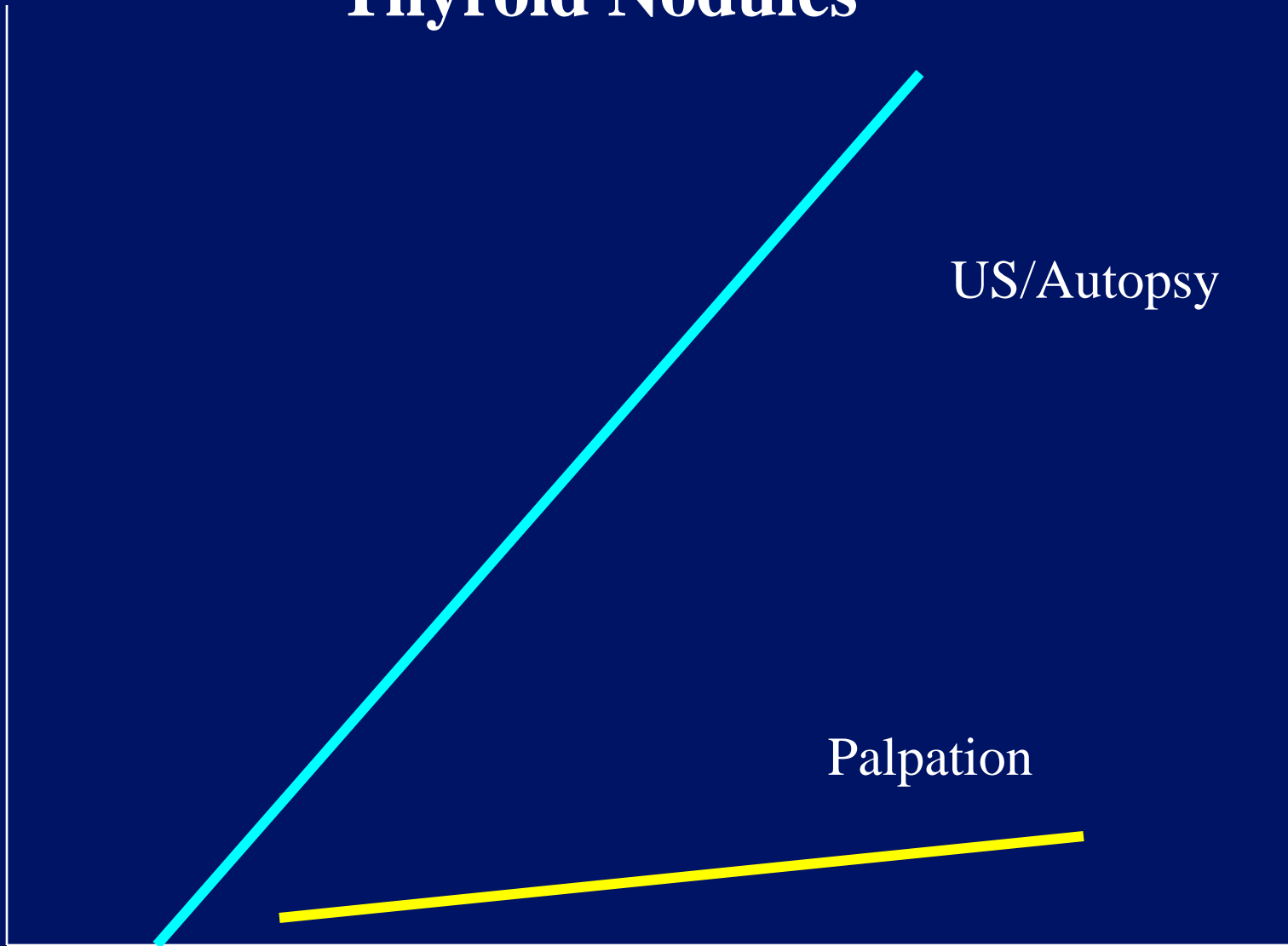
US/Autopsy

Palpation

50

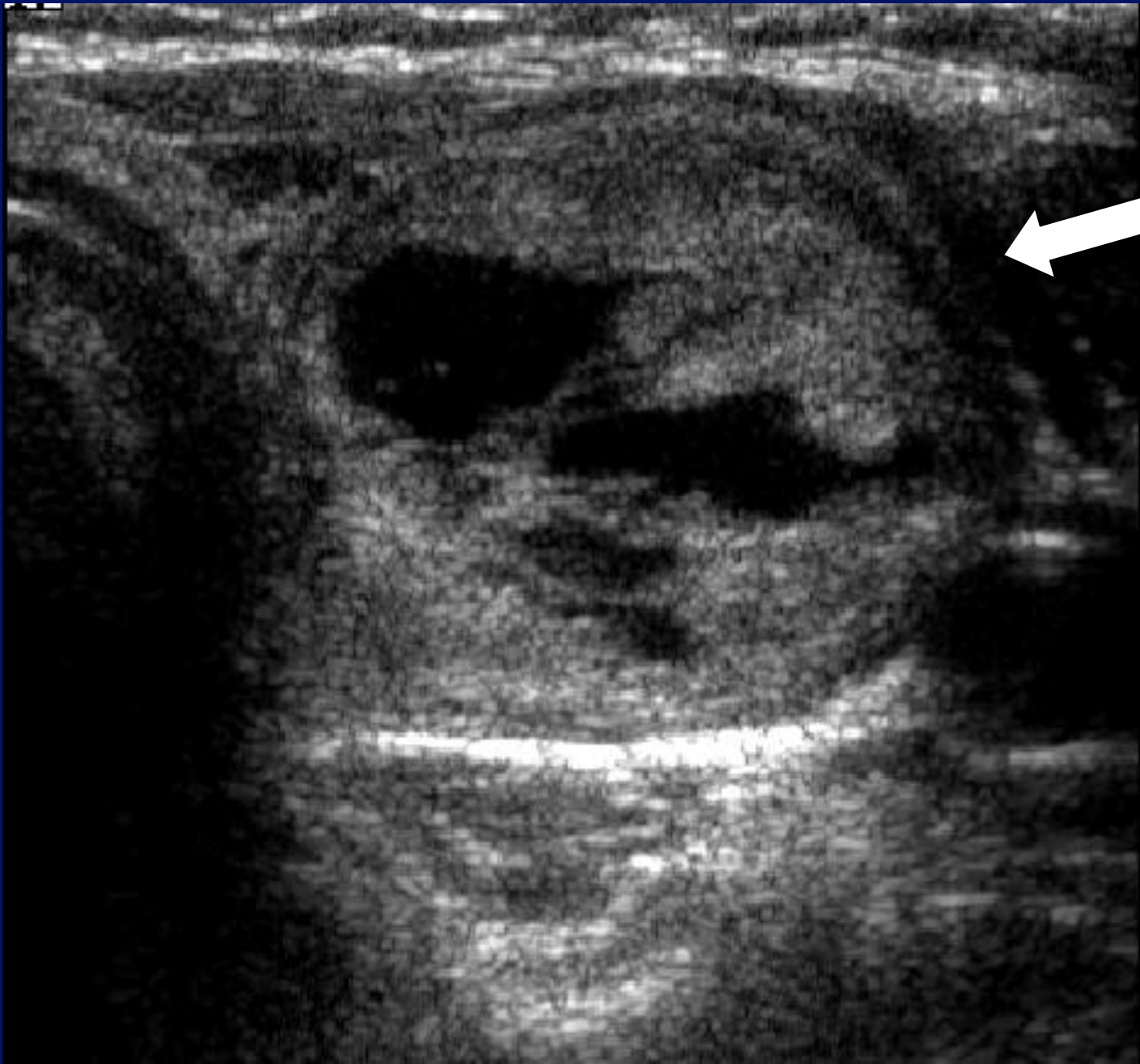
Age

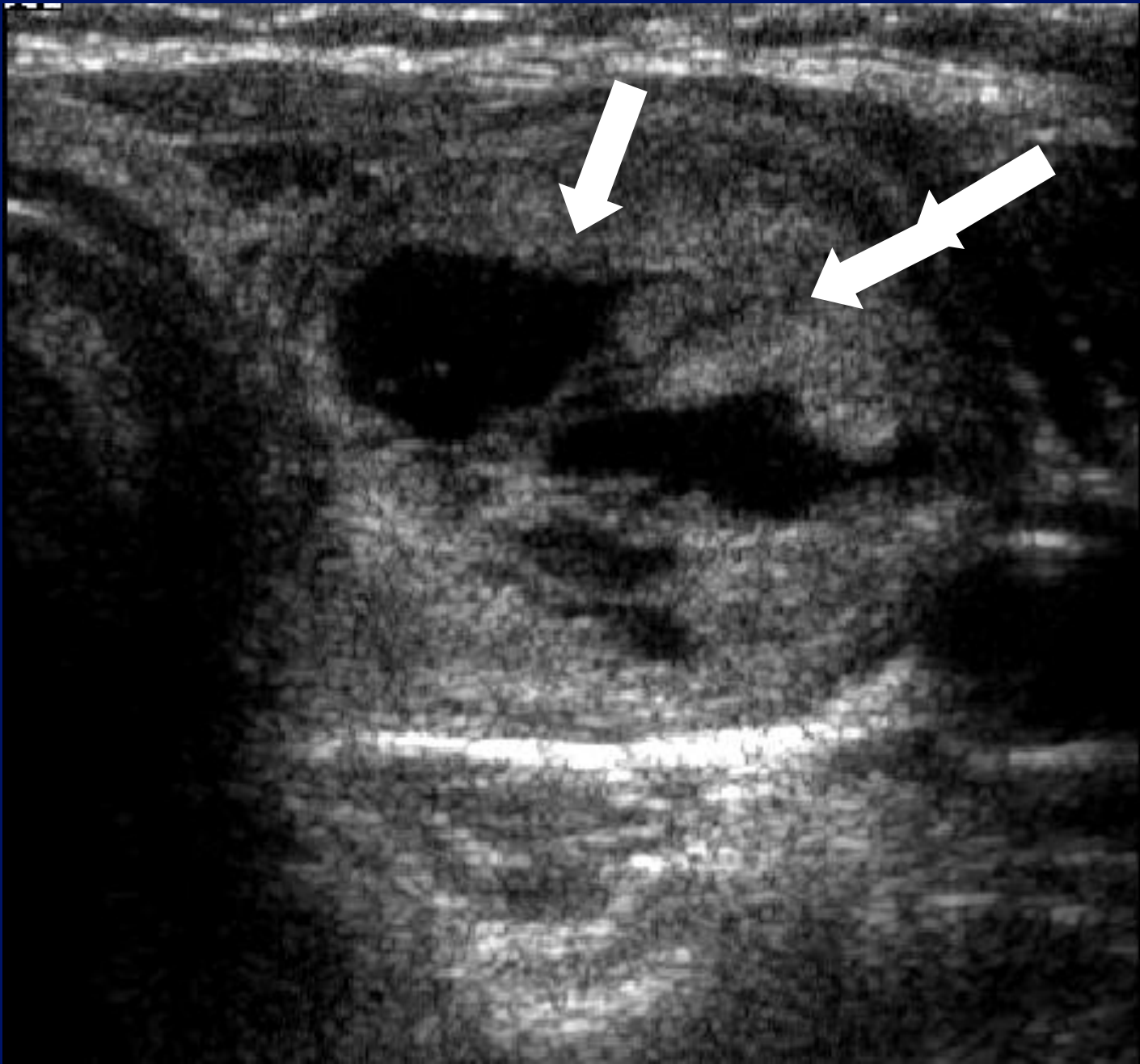
100



Incidence of malignancy?

- 1000 new cases per annum in England and Wales (0.002%)
- 1 new case per 50,000 , per year.
- 250,000 population = 5 new cases/year
- 500,000 population=10 new cases/year.

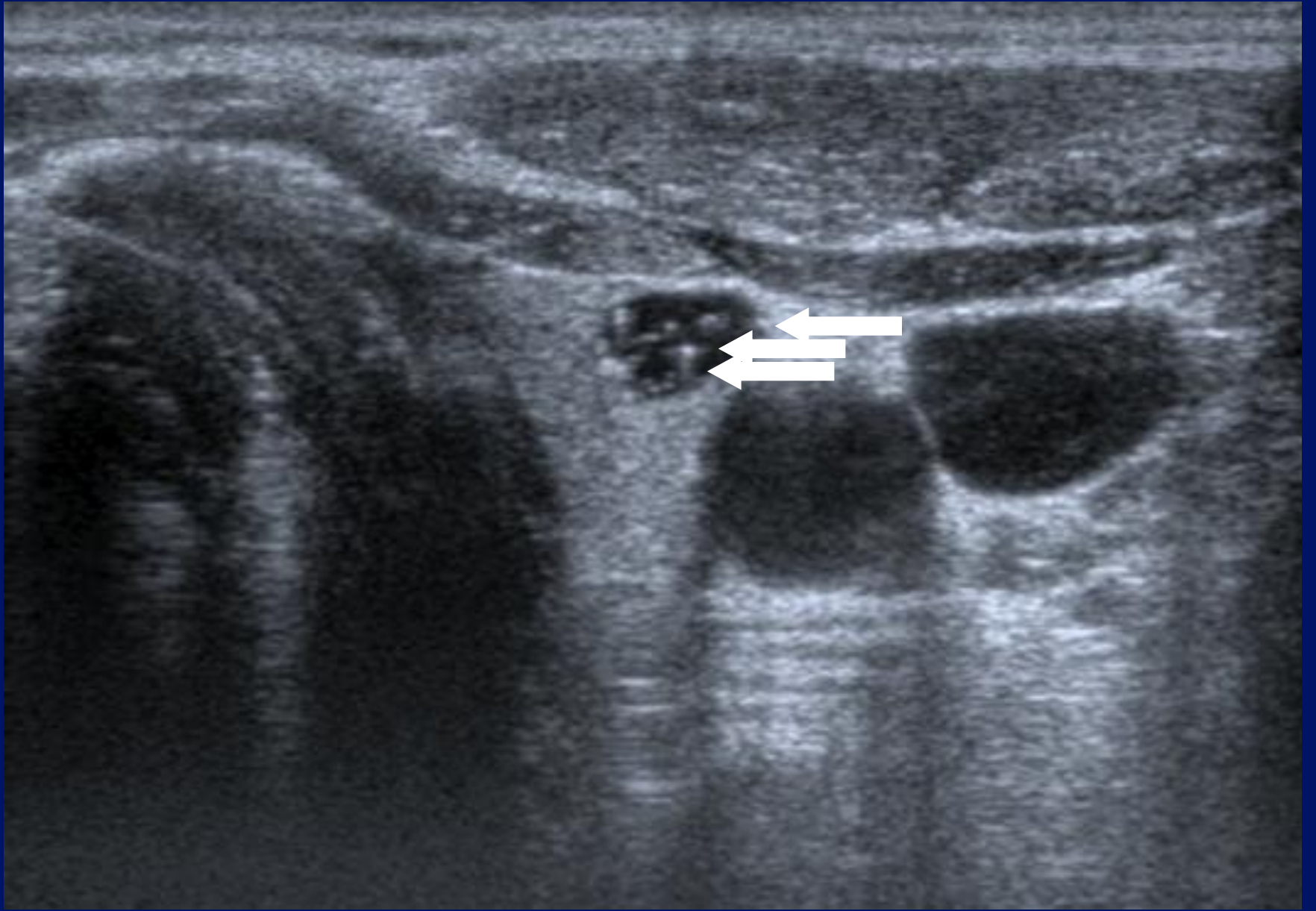


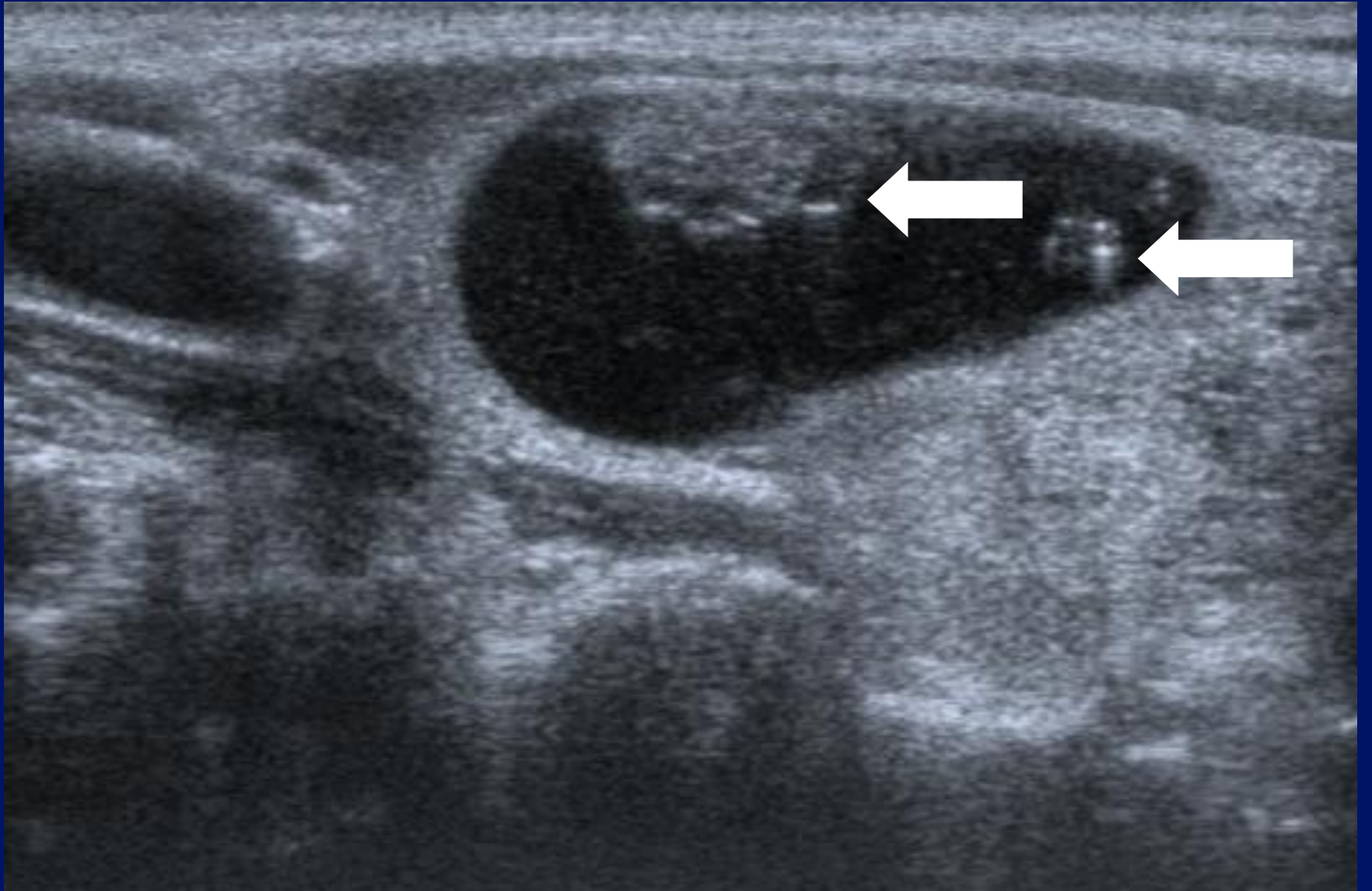


Signs?

- 426 resected nodules, surgical correlation
- Benign nodules :iso/hyper-echoic and contain cystic degenerative change with a perinodular hypoechoic rim

Brkljacic et al, J Clin US;22:71-76.1995.

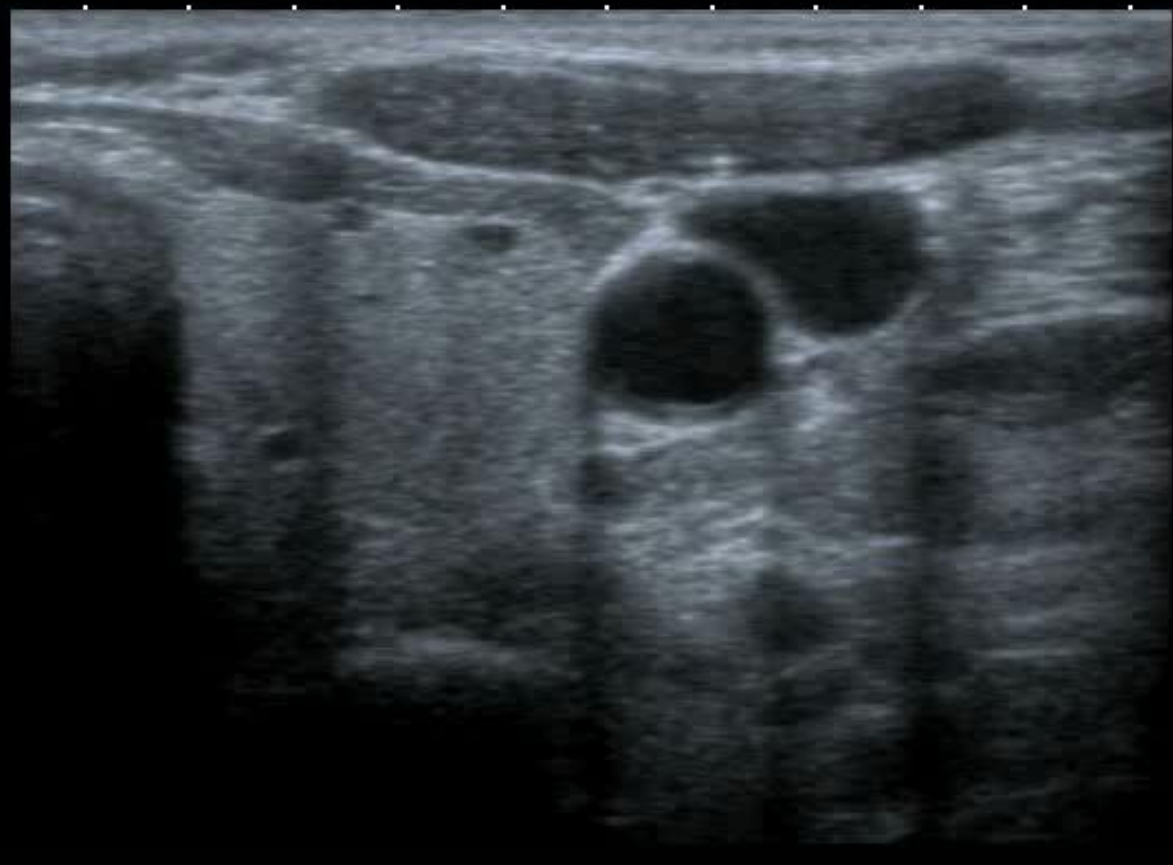






T

0 ♦
.
1 ♦
.
2 ♦
.
3 ♦
.
4 ♦



MI:1.6
2DG
85
DR
70

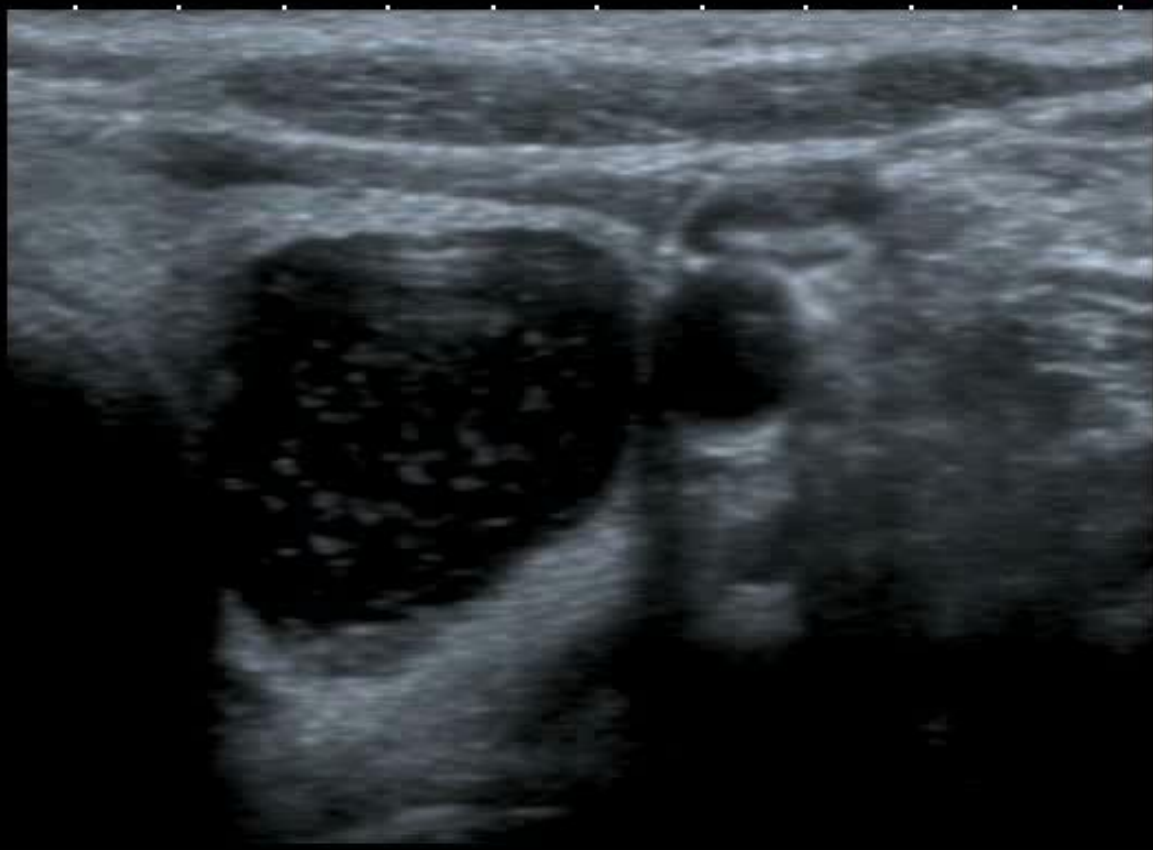12L5
T8.4
32 fps



APure



T 0
1
2
3
4



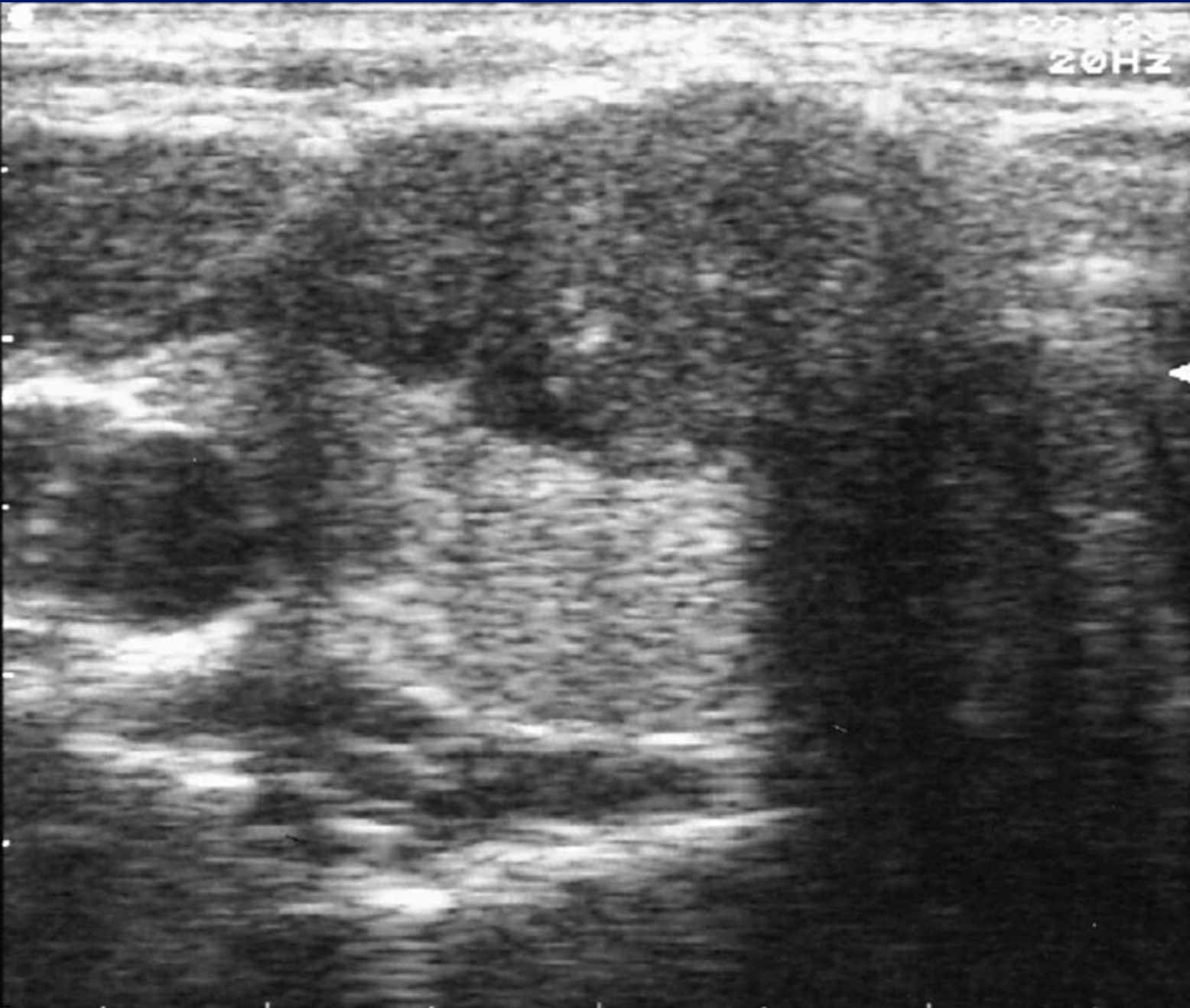
MI:1.6
2DG
85
DR
70

12L5
T9.0
21 fps



2012
20HZ

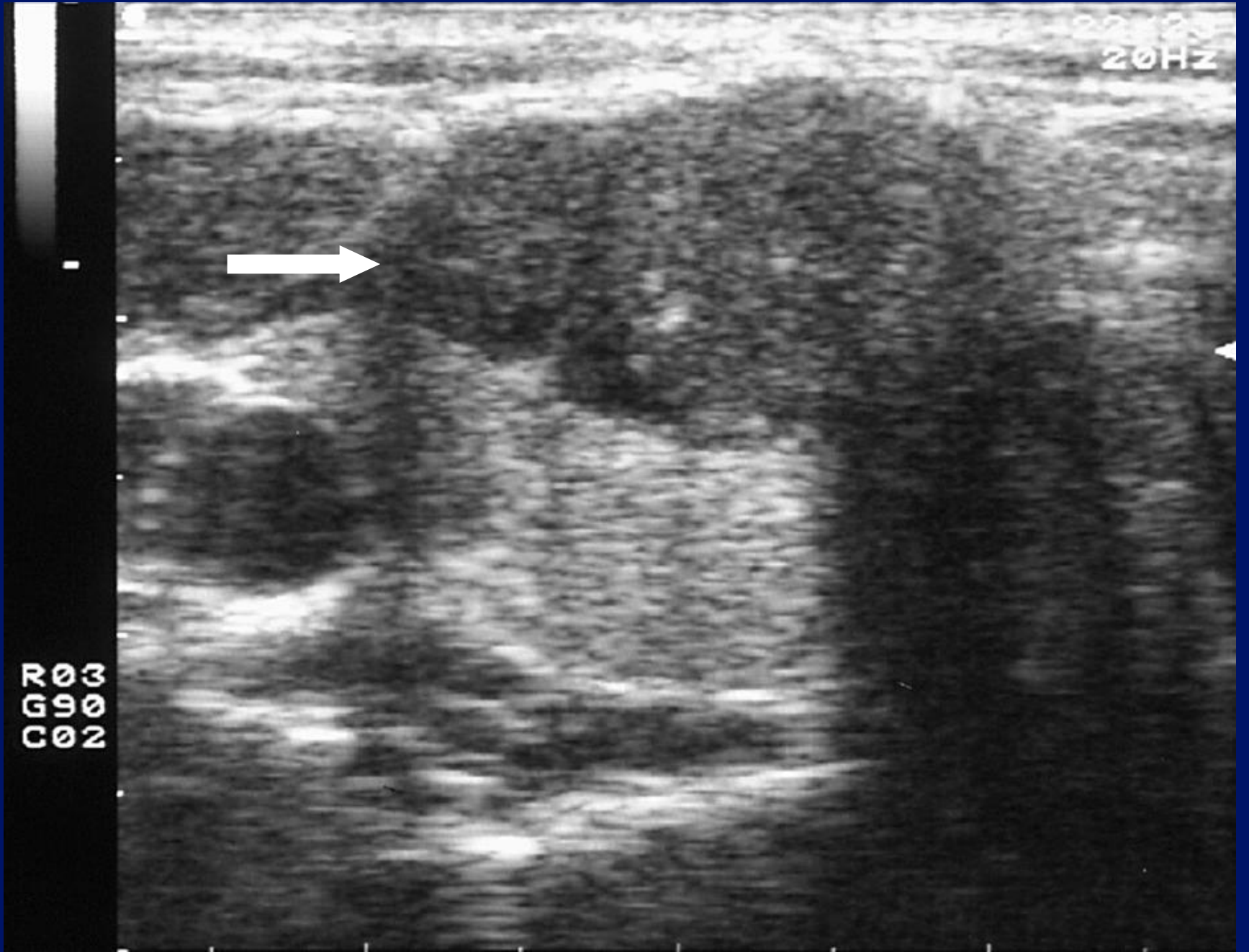
CGR
003
002



2012
20HZ



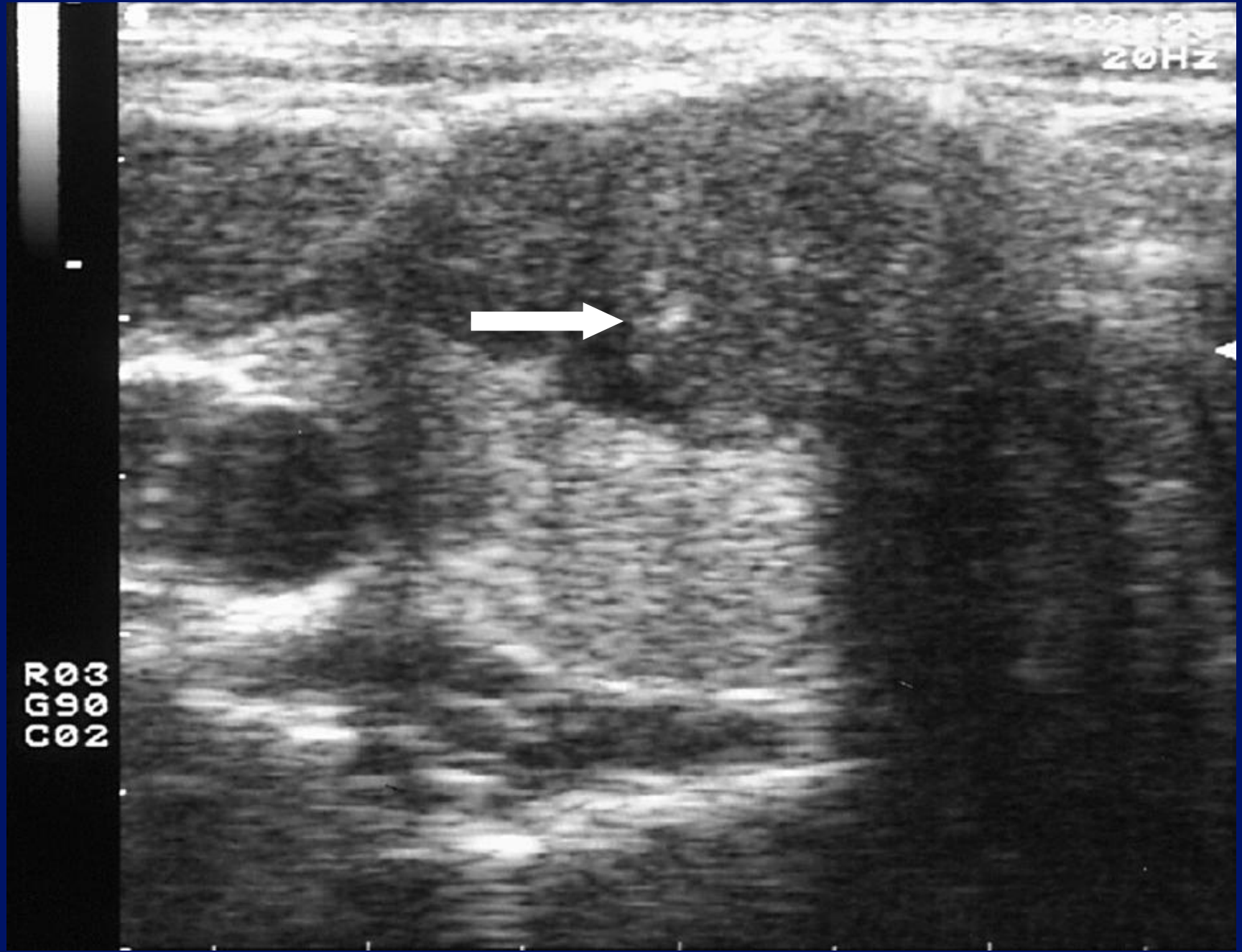
CGR03
C090
C02

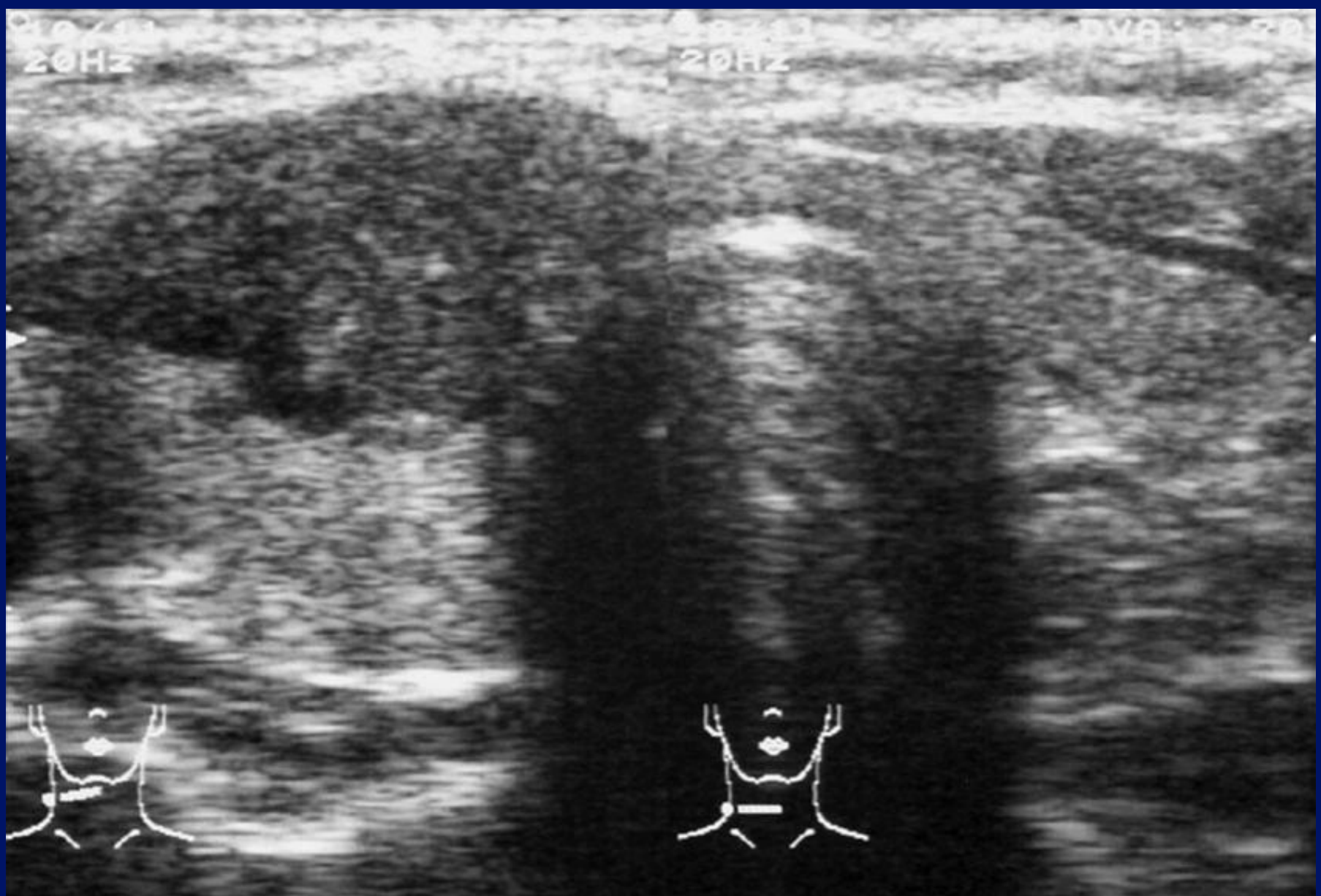

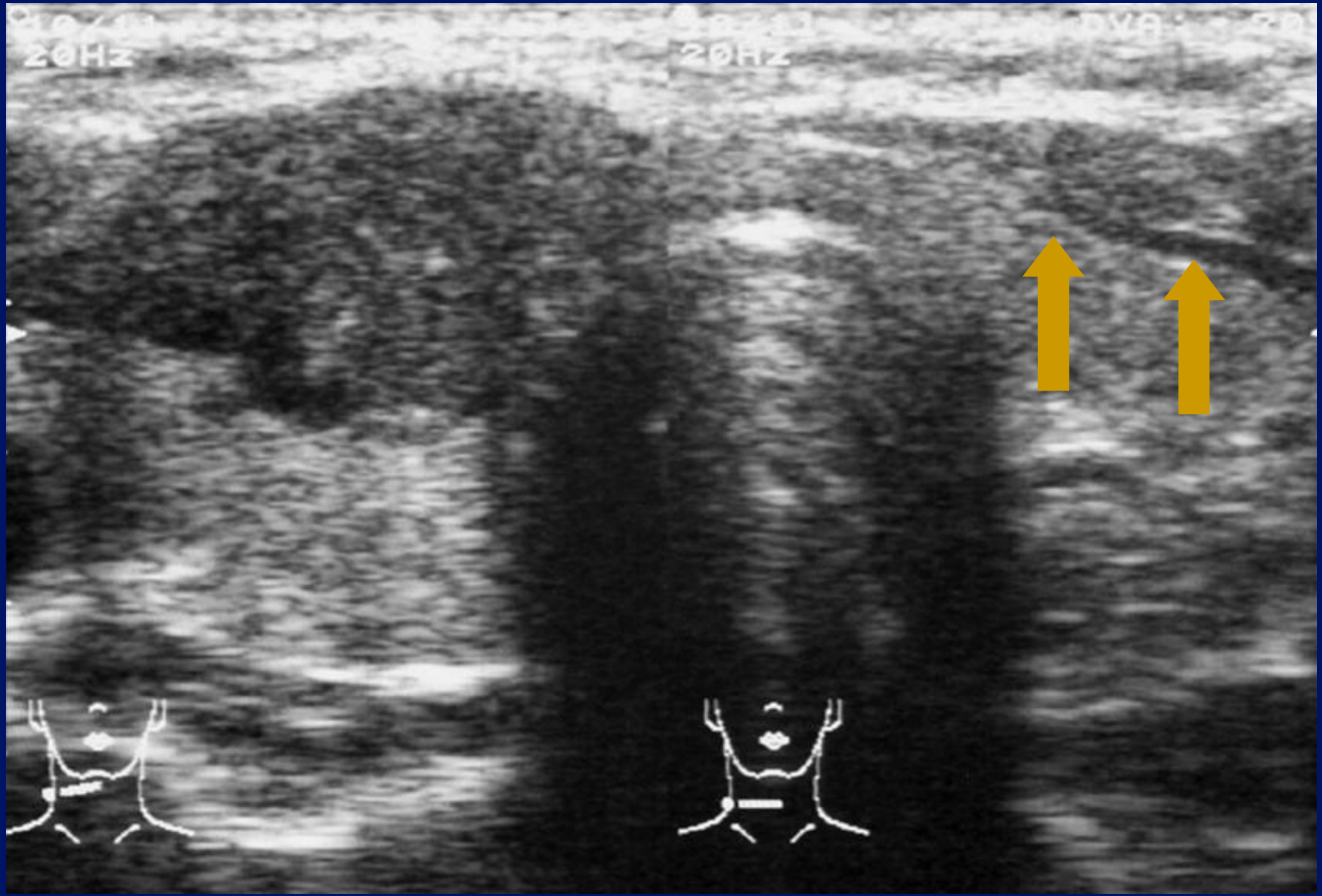
20123
20HZ

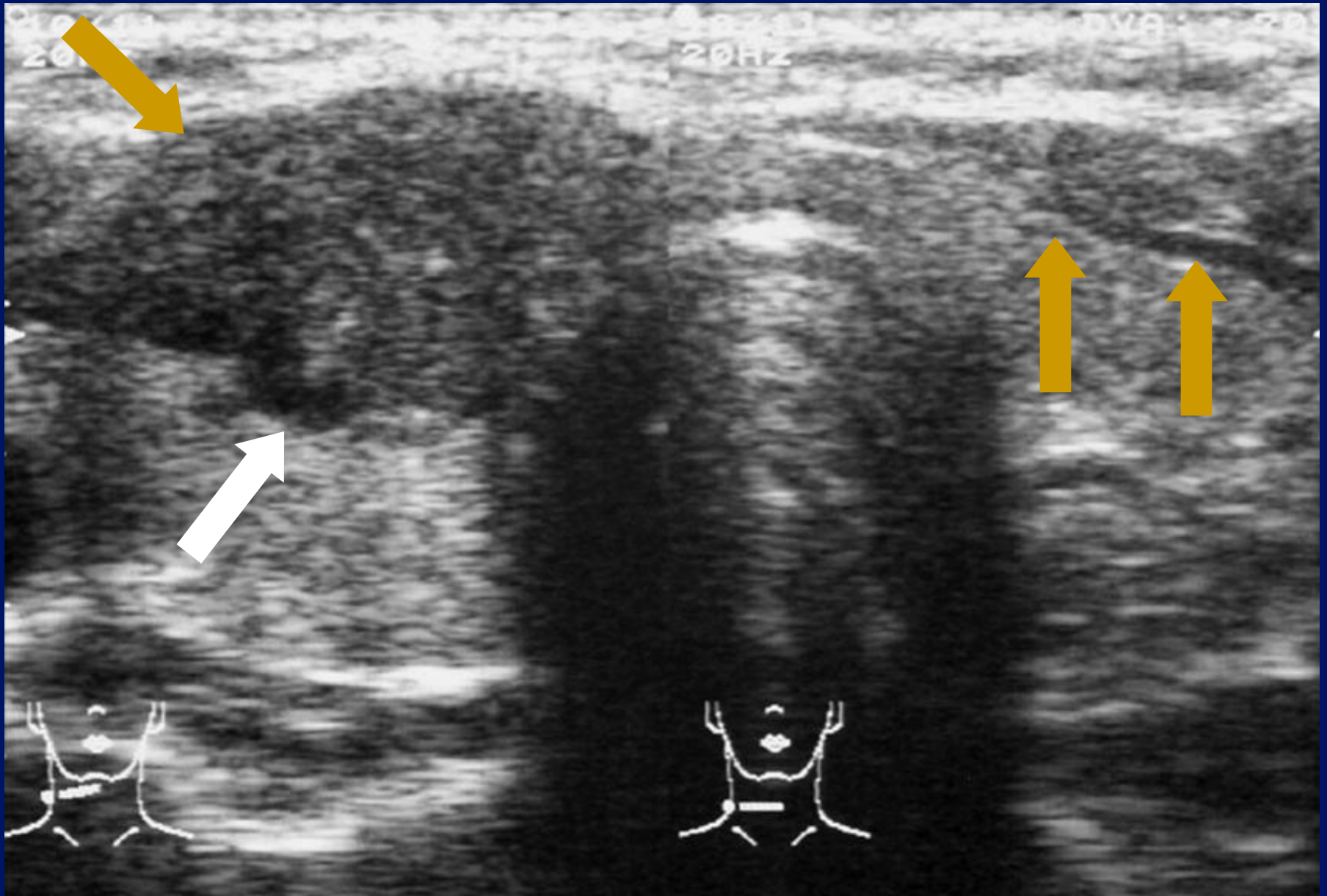


CGR03
C990
C02









Incidence of Papillary carcinoma?

- 6,499 patients:US and FNAC
- 164 cases(incidence : 2.52%) of malignancy :

116 Papillary Ca

23 Follicular Ca

6 Medullary Ca

7 Anaplastic Ca

8 Hurthle Cell Ca

4 Lymphomas

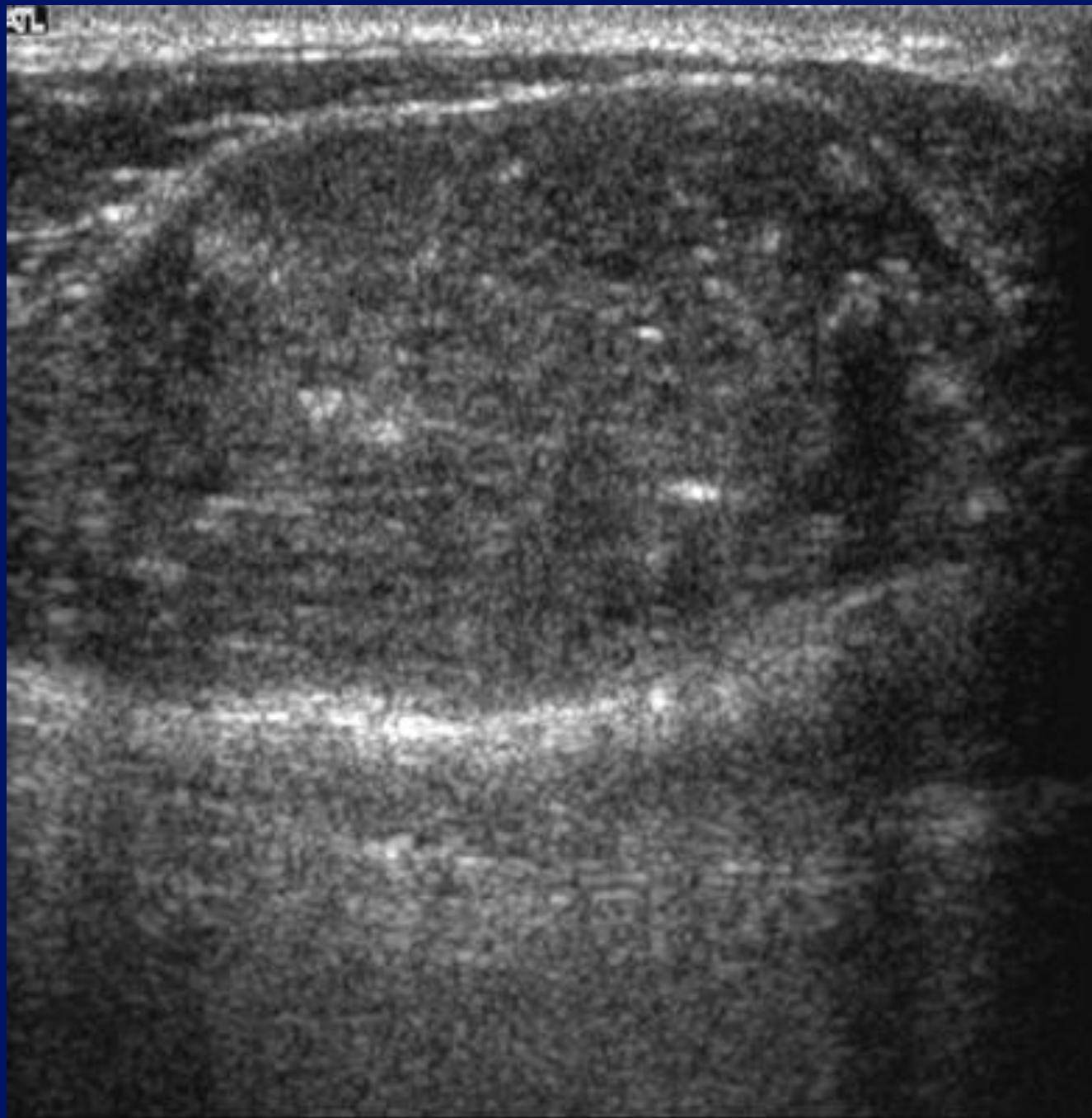
Lin et al,Acta

Cytol,1997;41:687-691.

Occult Incidence.

- Autopsy series.
- Small (less than 1cm) papillary tumours :
“micro-carcinomas”.
- Reported incidence : 10-30%.

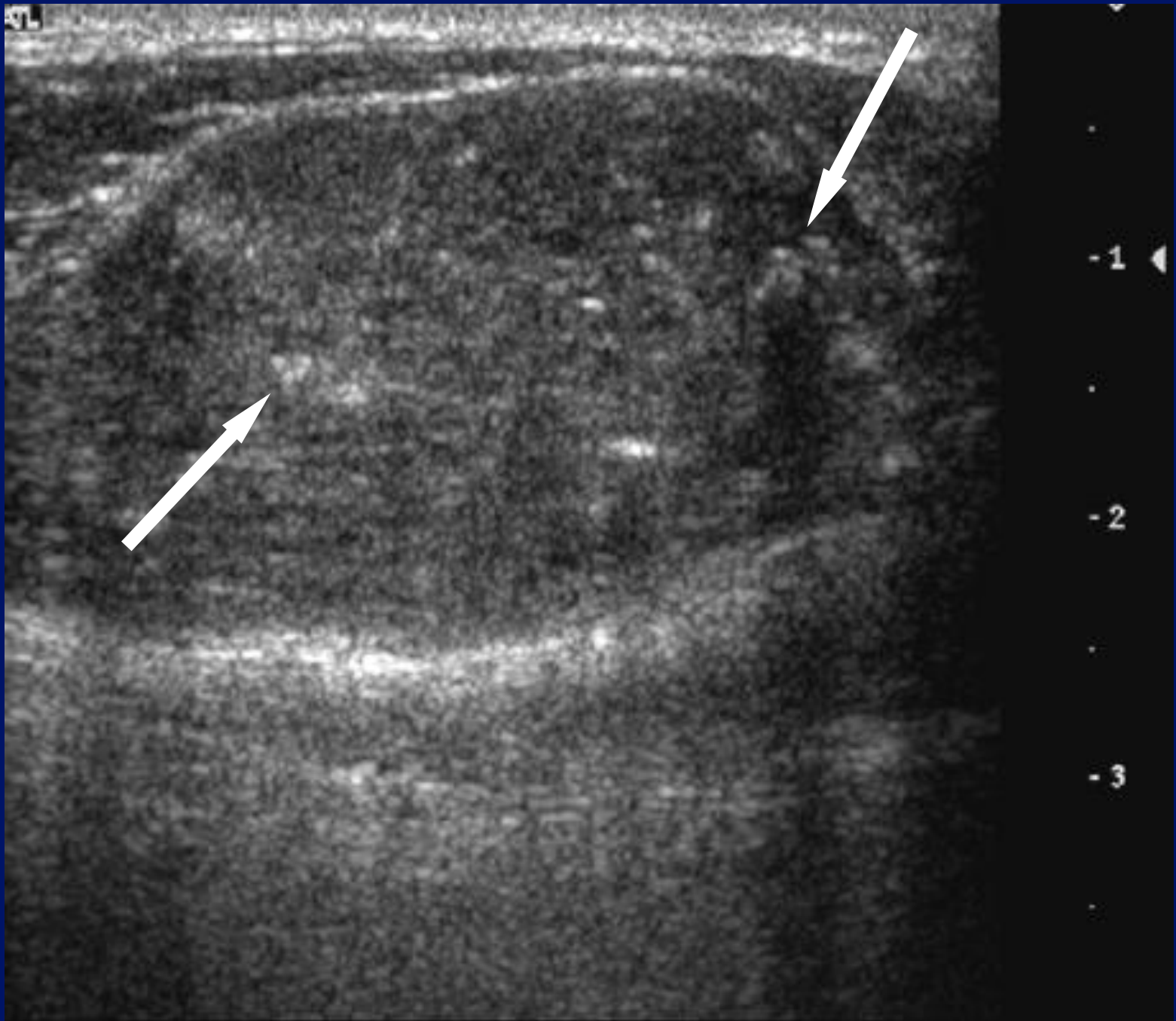
5L



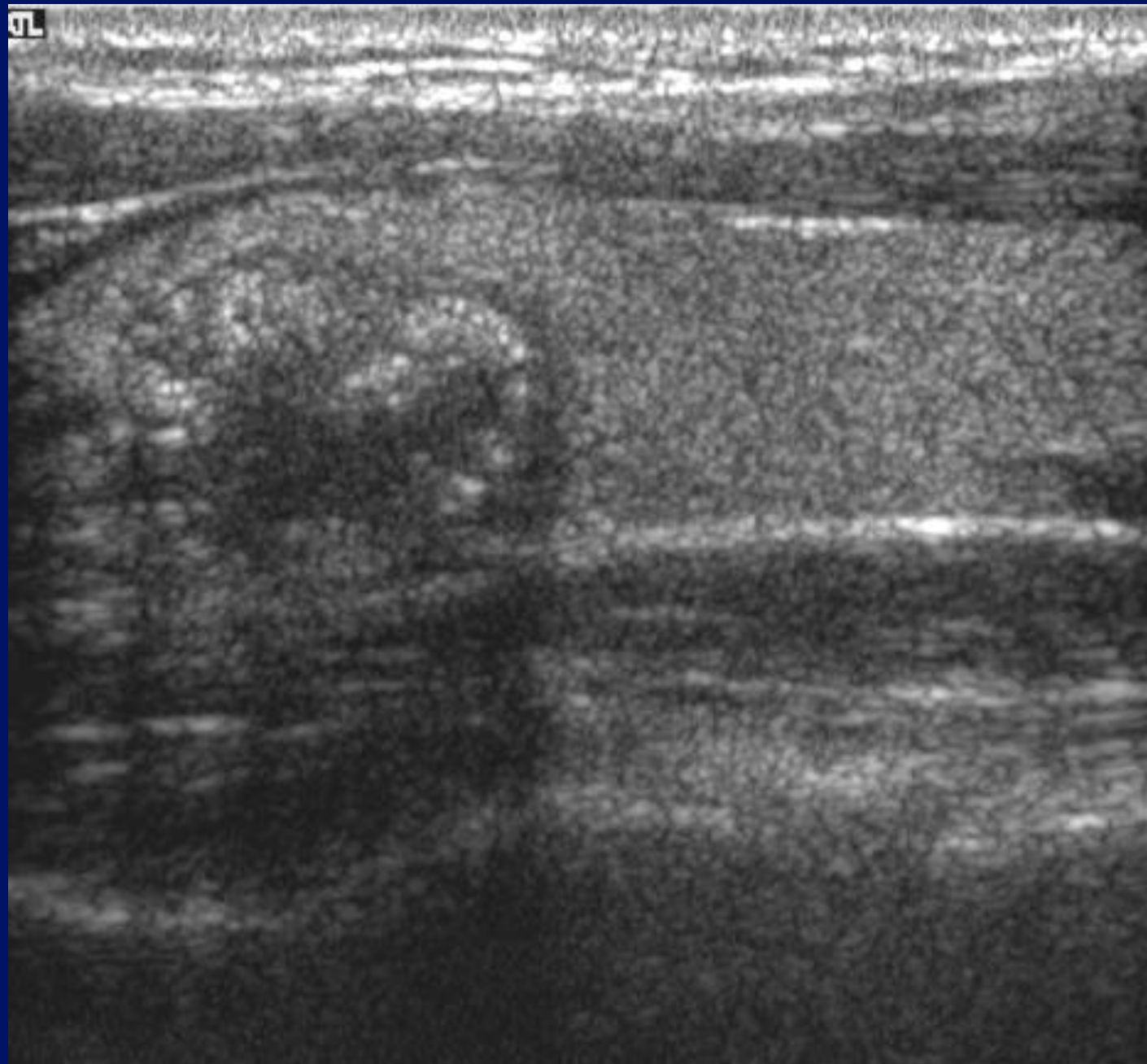
-1

-2

-3



5

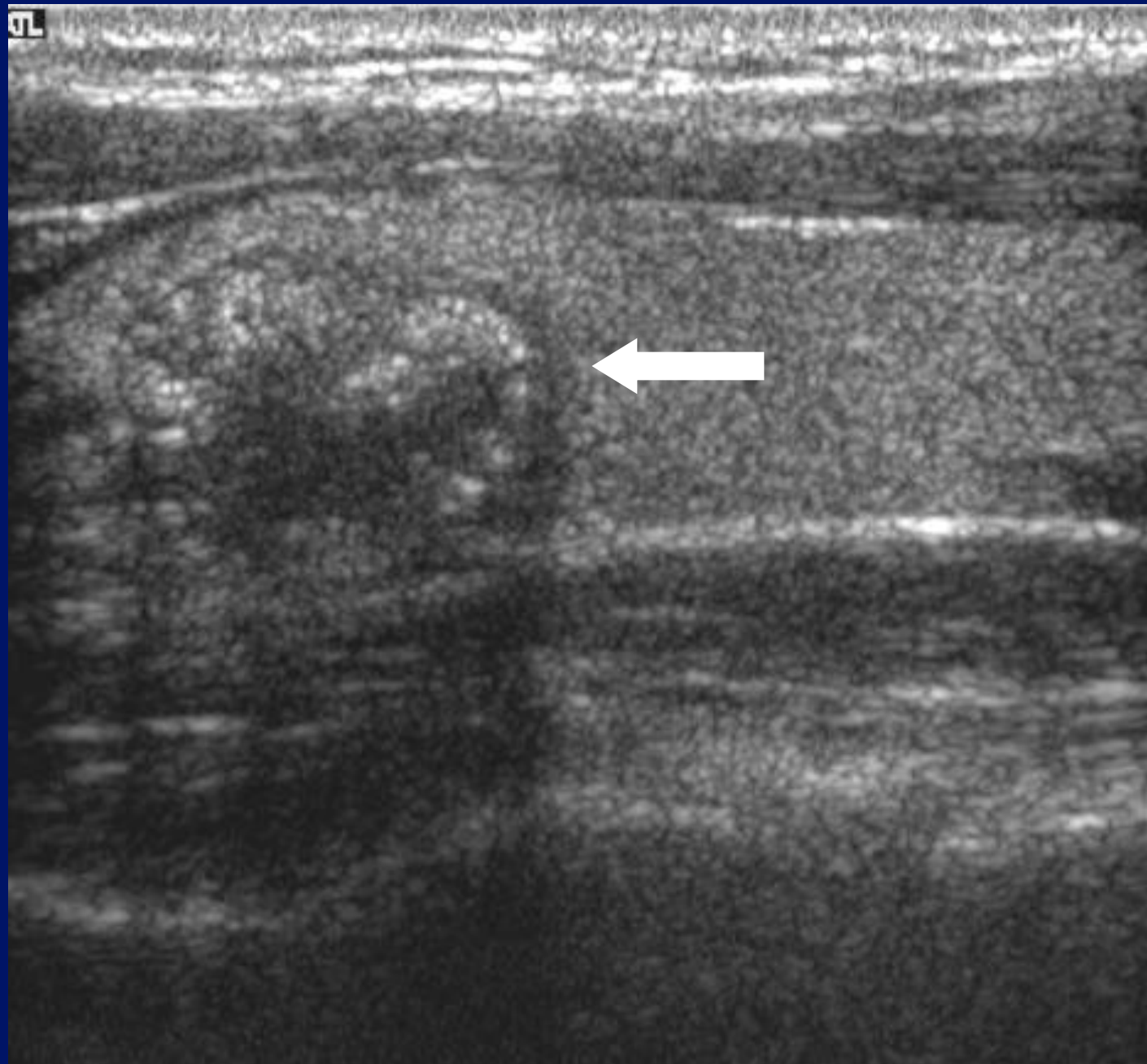


-1 ◀

-2

-3

5



-1 ◀

-2

-3

Signs: papillary carcinoma?

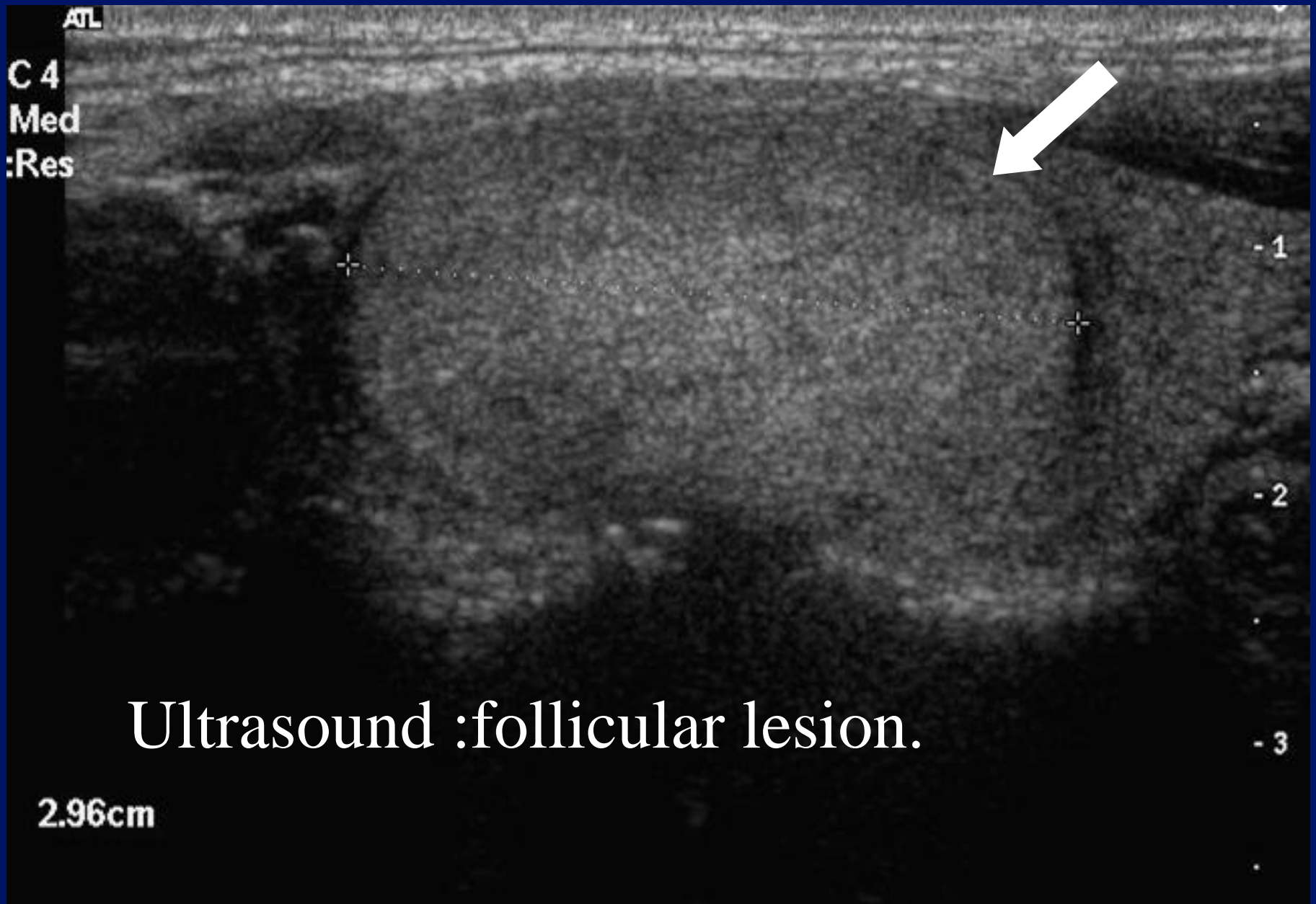
- Combination of absent halo, microcalcification and type III (marked intranodular flow) most specific
- Specificity: 97.2%
- Sensitivity: 16.6%

Rago et al, Eur J
Endocrinol., 1998; 138, 41-46

Follicular carcinoma.

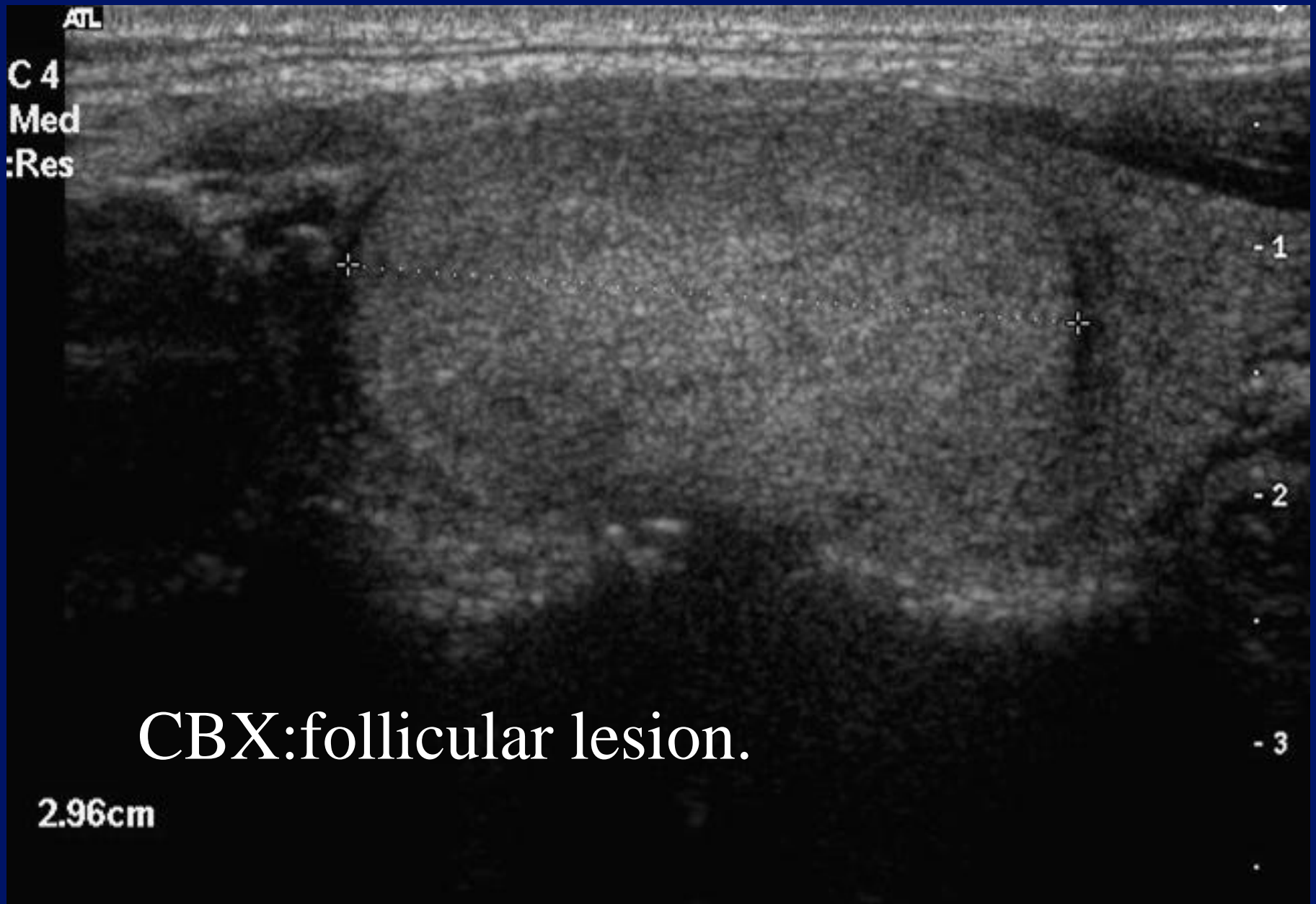
Follicular lesions.

- Spectrum from adenoma to carcinoma.
- 80% will be benign
- Follicular carcinoma – 10-15% of all thyroid Ca.
- Cytology of no use.
- Histology of no use in differentiation.
- Surgical specimen : vascular and capsular invasion – follicular carcinoma.



Ultrasound :follicular lesion.

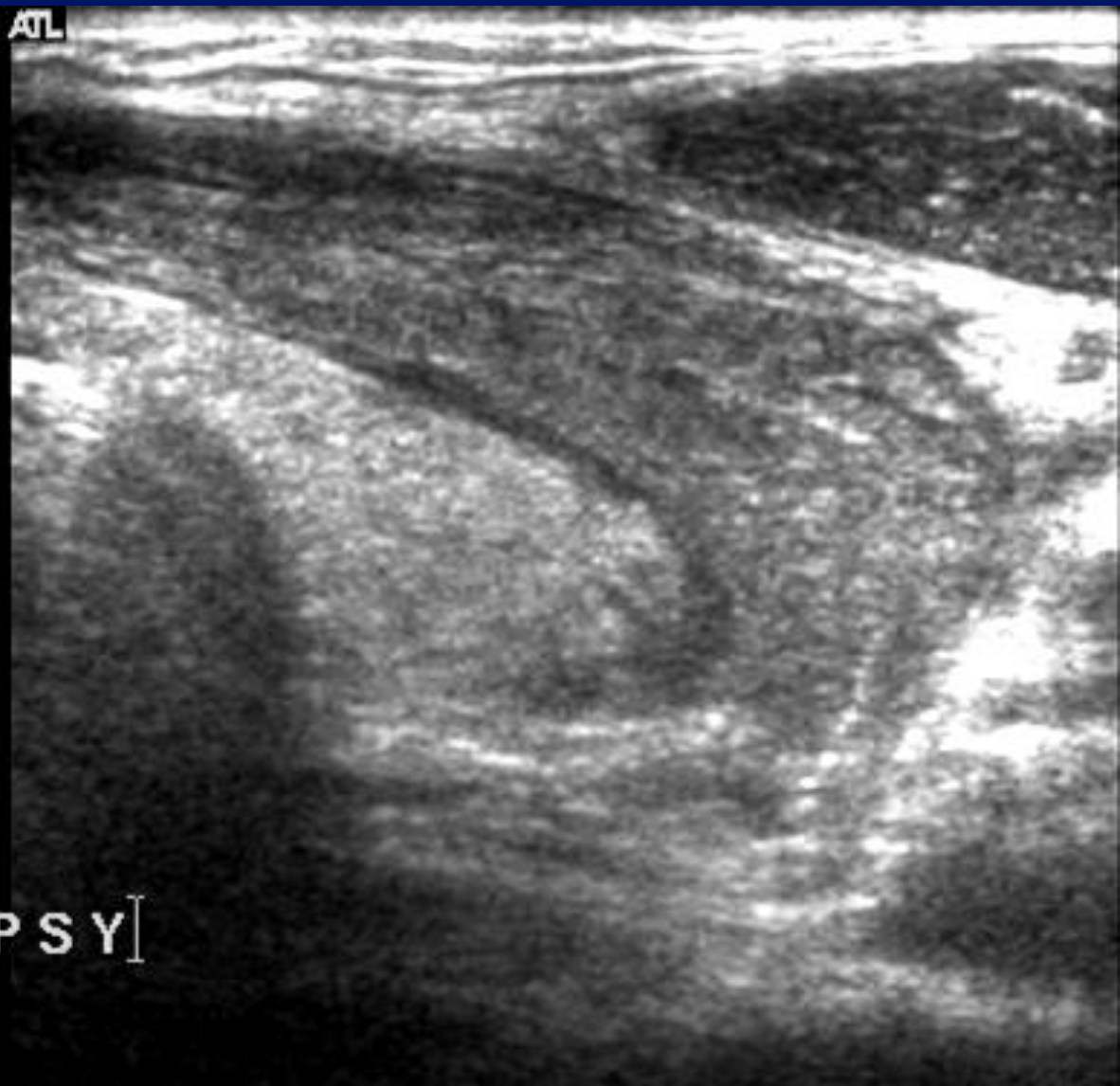2.96cm



CBX:follicular lesion.

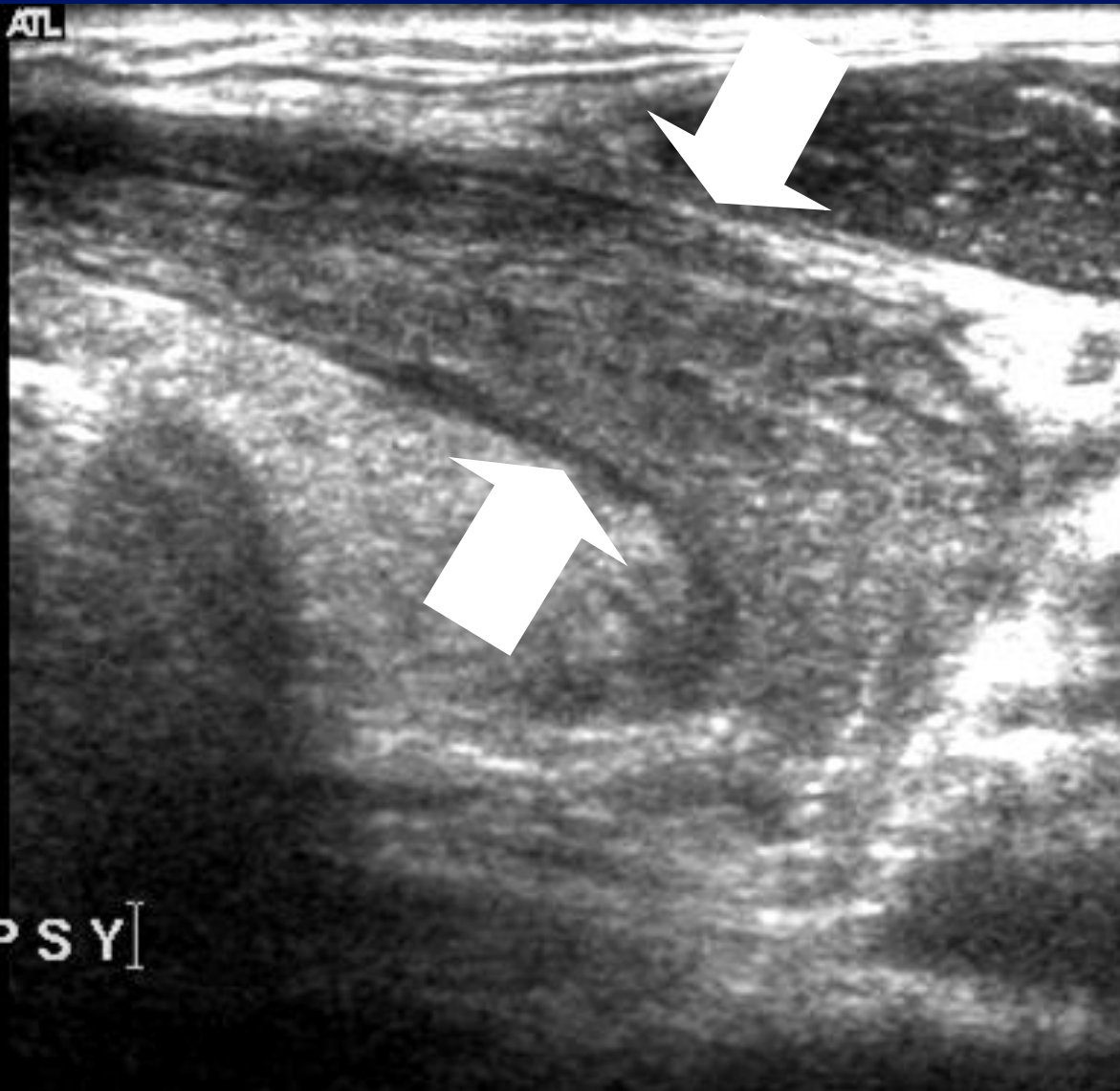
2.96cm

Map 3
170dB/C 2
Persist Off
2D Opt:FSCT
Fr Rate:Surv
SonoCT™



POST BIOPSY

Map 3
170dB/C 2
Persist Off
2D Opt:FSCT
Fr Rate:Surv
SonoCT™



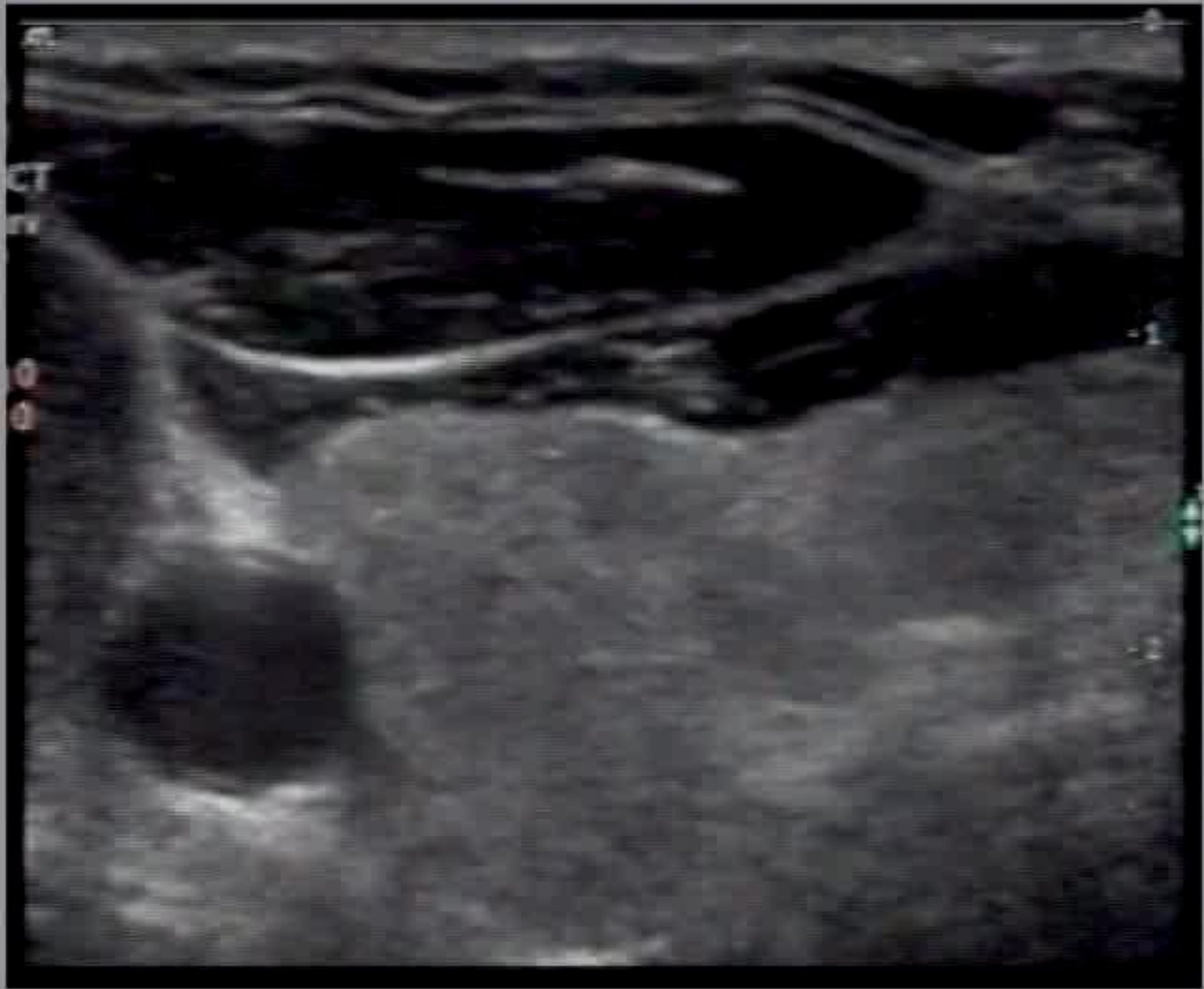
Follicular lesions.

- Adenomas : solid,homogenous,iso/hyper-echoic.
- Well defined halo.
- Carcinoma : solid ,hypo-echoic areas within.

Medullary carcinoma.



Medullary Carcinoma Thyroid



- Typically hypo-echoic.
- Contains calcification.
- Calcification more “globular”.
- “Calcification” may be amyloid.




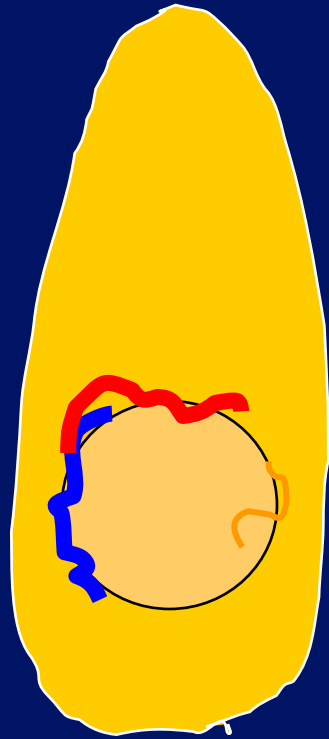
Signs?





























Predictors of Cancer.

	Sensitivity	Specificity
• Micro-calcifications	40%	90%
• Absence of halo	66%	46%
• Irregular margins	64%	84%
• Hypo-echoic	83%	49%
• Intra-nodular flow	70%	65%
• MicroCa. & irreg m.	30%	95%
• MicroCa. & hypoechoic	28%	95%
• Solid & hypoechoic	73%	69%



Predictors of Cancer.




Sensitivity



Specificity

• Micro-calcifications	40%	90%
• Absence of halo	66%	46%
• Irregular margins	64%	84%
• Hypo-echoic	83%	49%
• Intra-nodular flow	70%	65%
• MicroCa. & irreg m.	30%	95%
• MicroCa. & hypoechoic	28%	95%
• Solid & hypoechoic	73%	69%




Predictors of Cancer.

	Sensitivity	Specificity
• Micro-calcifications	40%	90%
• Absence of halo	66%	46%
• Irregular margins	64%	84%
 • Hypo-echoic	83%	49%
• Intra-nodular flow	70%	65%
• MicroCa. & irreg m.	30%	95%
• MicroCa. & hypoechoic	28%	95%
• Solid & hypoechoic	73%	69%

Predictors of Cancer.

	Sensitivity	Specificity
• Micro-calcifications	40%	90%
• Absence of halo	66%	46%
• Irregular margins	64%	84%
 • Hypo-echoic	83%	49%
• Intra-nodular flow	70%	65%
• MicroCa. & irreg m.	30%	95%
• MicroCa. & hypoechoic	28%	95%
 • Solid & hypoechoic	73%	69%

Predictors of Cancer.



	Sensitivity	Specificity
• Micro-calcifications	40%	90%
• Absence of halo	66%	46%
• Irregular margins	64%	84%
 • Hypo-echoic	83%	49%
 • Intra-nodular flow	70%	65%
• MicroCa. & irreg m.	30%	95%
• MicroCa. & hypoechoic	28%	95%
 • Solid & hypoechoic	73%	69%

Predictors of Cancer.




Sensitivity  Specificity

• Micro-calcifications	40%	90%
• Absence of halo	66%	46%
• Irregular margins	64%	84%
• Hypo-echoic	83%	49%
• Intra-nodular flow	70%	65%
• MicroCa. & irreg m.	30%	95%
• MicroCa. & hypoechoic	28%	95%
• Solid & hypoechoic	73%	69%

Predictors of Cancer.

	Sensitivity	Specificity
• Micro-calcifications	40%	90%
• Absence of halo	66%	46%
• Irregular margins	64%	84%
• Hypo-echoic	83%	49%
• Intra-nodular flow	70%	65%
 MicroCa. & irreg m.	30%	95%
 MicroCa. & hypoechoic	28%	95%
• Solid & hypoechoic	73%	69%

Predictors of Cancer.

	Sensitivity	Specificity
 Micro-calcifications	40%	90%
• Absence of halo	66%	46%
• Irregular margins	64%	84%
• Hypo-echoic	83%	49%
• Intra-nodular flow	70%	65%
 MicroCa. & irreg m.	30%	95%
 MicroCa. & hypoechoic	28%	95%
• Solid & hypoechoic	73%	69%

Thyroid nodules.

- Sorting out nodules.
- Learn from others – Breast Radiologists.
- R Classification.
- Cytological classification(1 -5)
- Clinical scenario.
- Correctly manage patient.

Breast nodules – R classification..

R

1 : Normal.

2 : Probably benign.

3 : Indeterminate.

4 : Suspicious.

5 : Malignant


Nodules – R classification.....thyroid?



R

- 1 : Normal.
- 2 : Probably benign.
- 3 : Indeterminate.
- 4 : Suspicious.
- 5 : Malignant






R 1



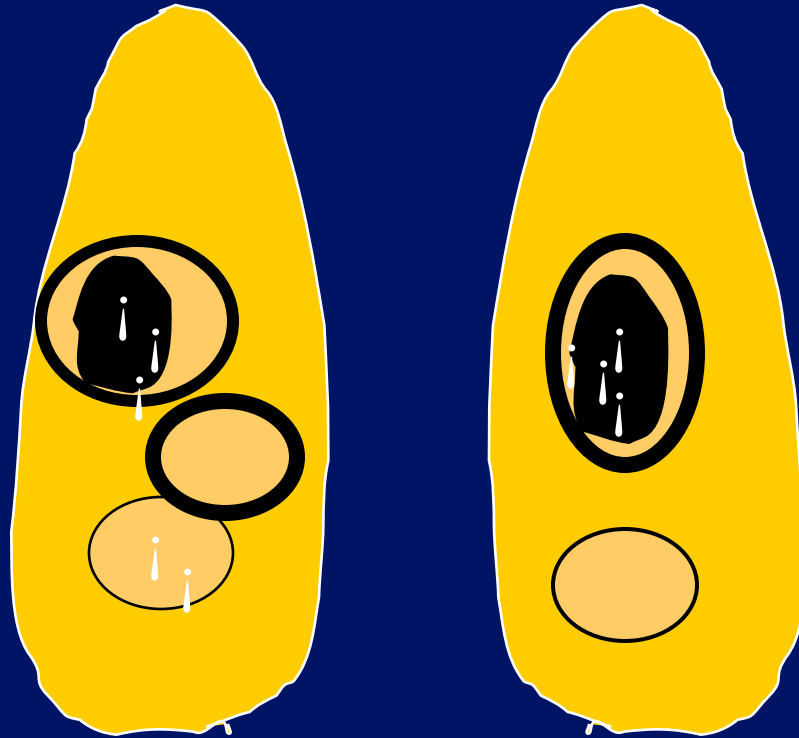


R 2

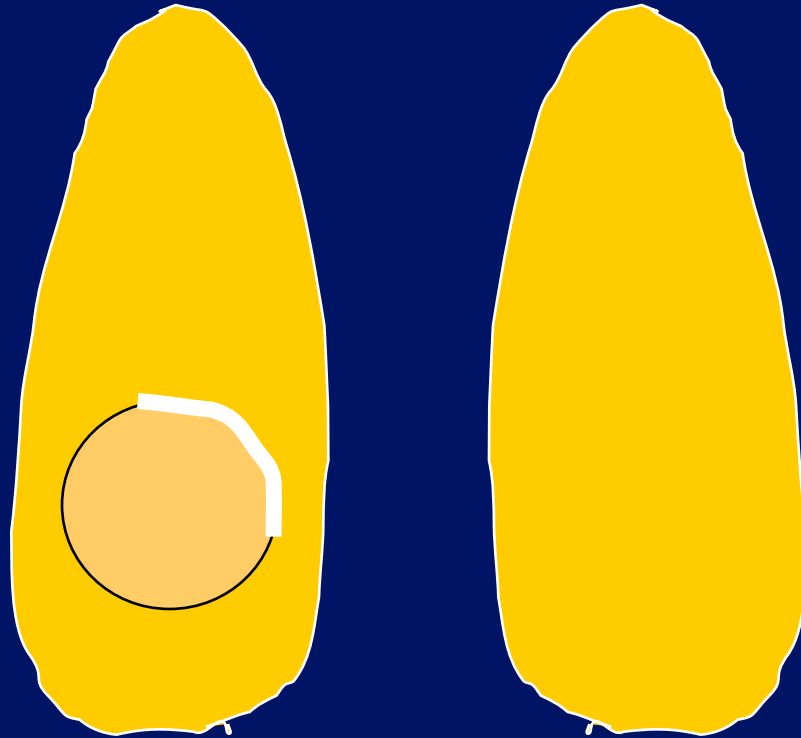




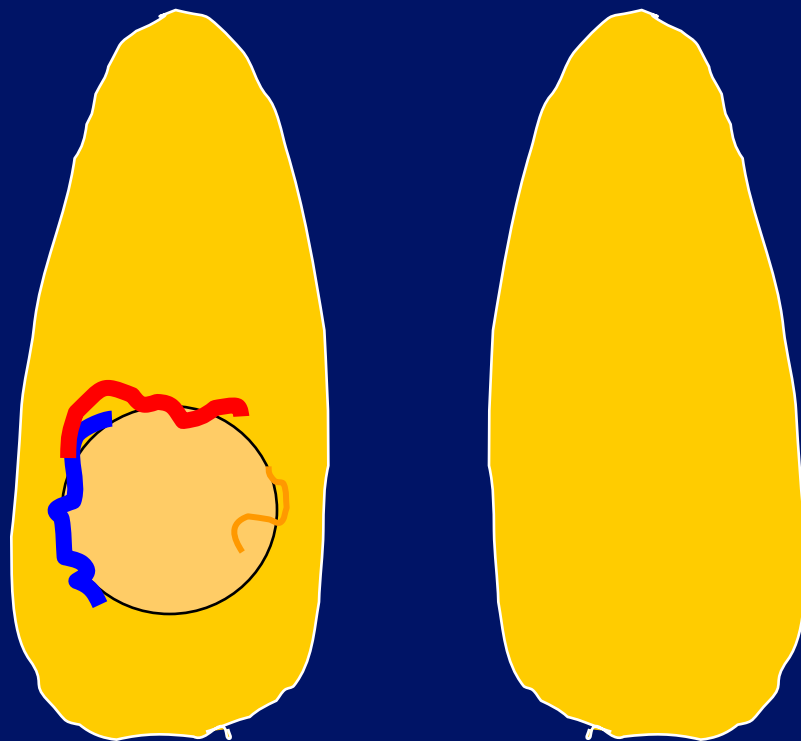
R 2




R 2

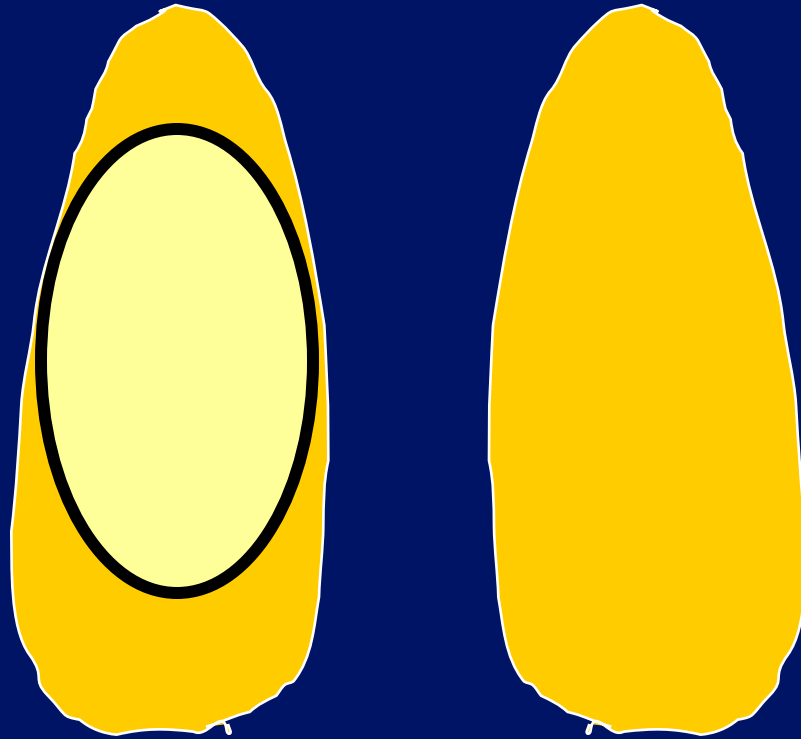


R 2






R 3

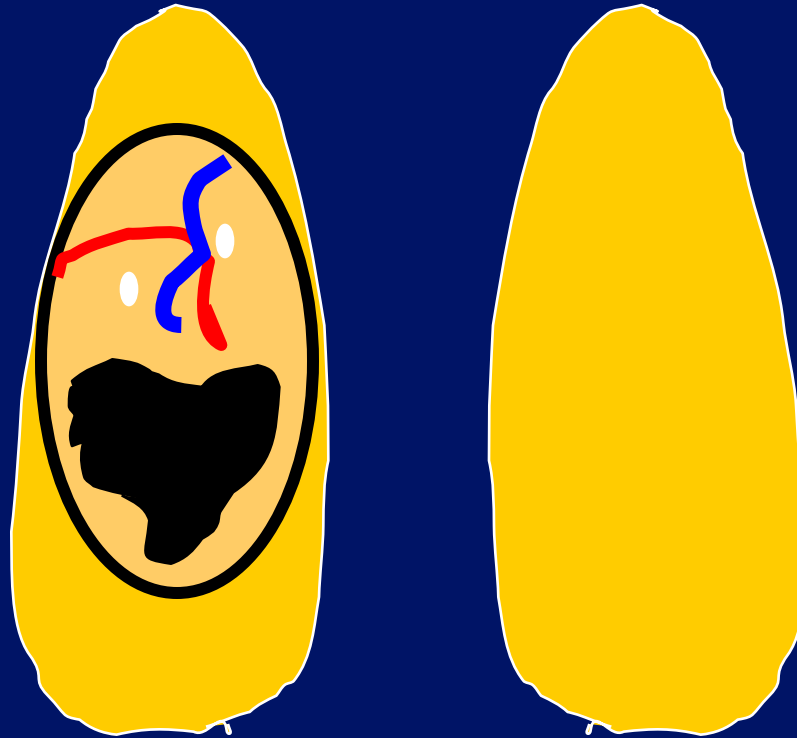




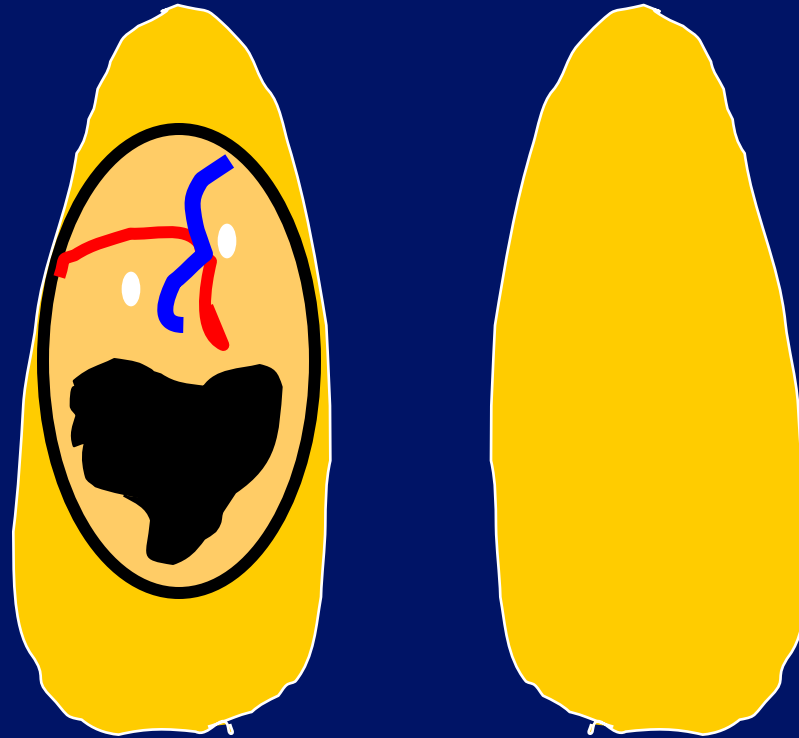
R ?



R ?

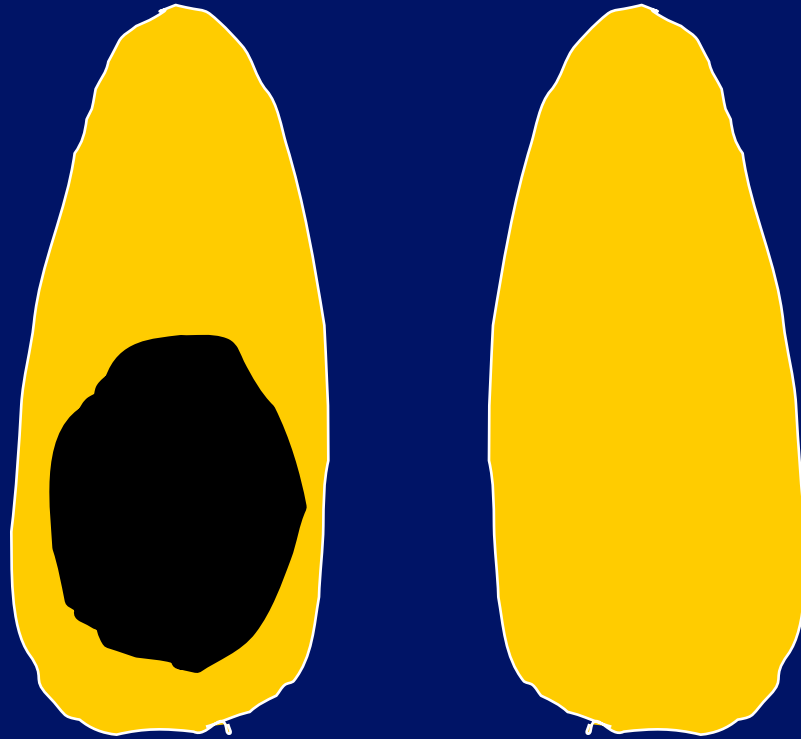


R 3





R 4



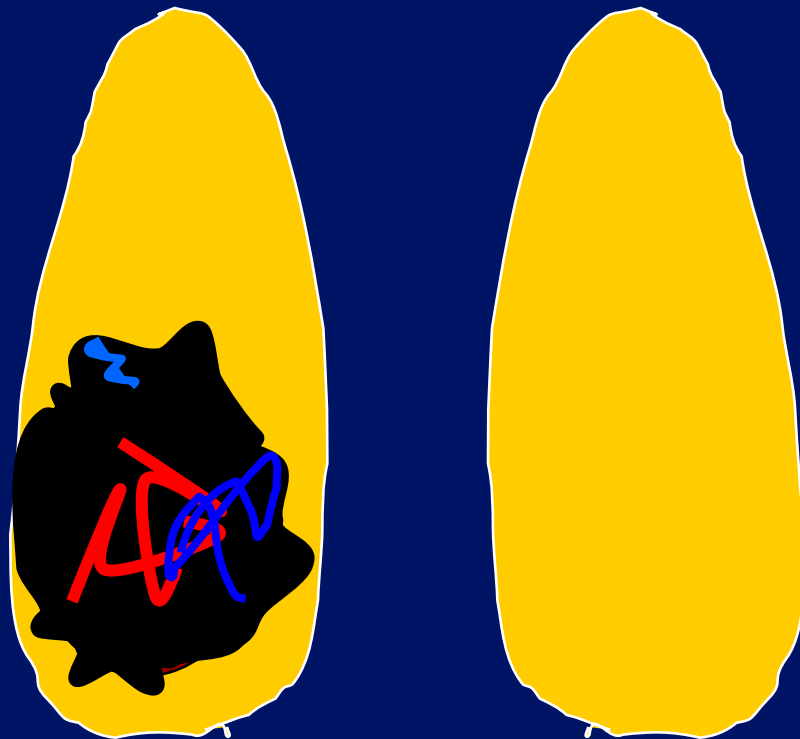



R 4/5



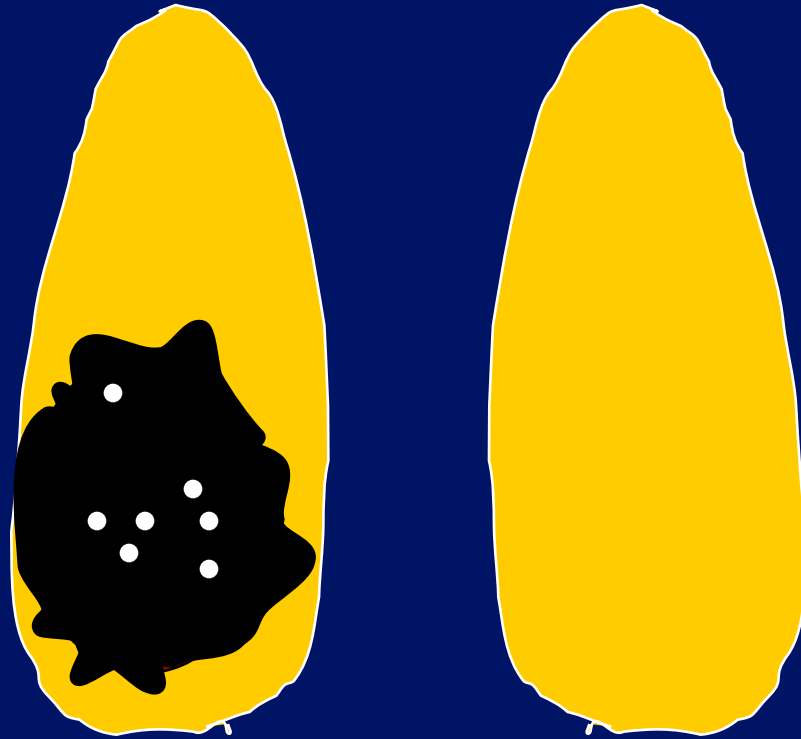




R 5






R 5





R 5

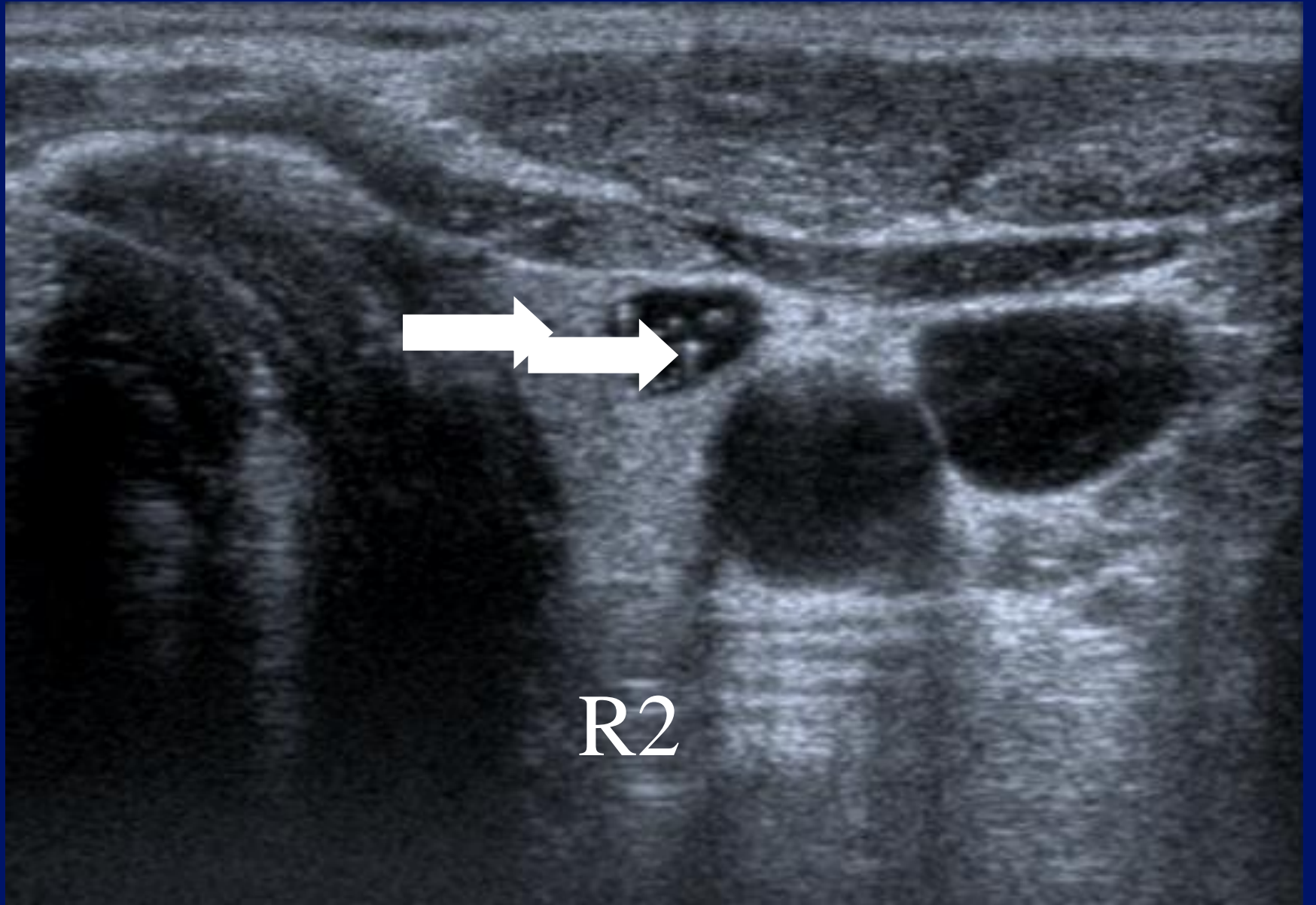


Lymphoma

Thyroid nodules.

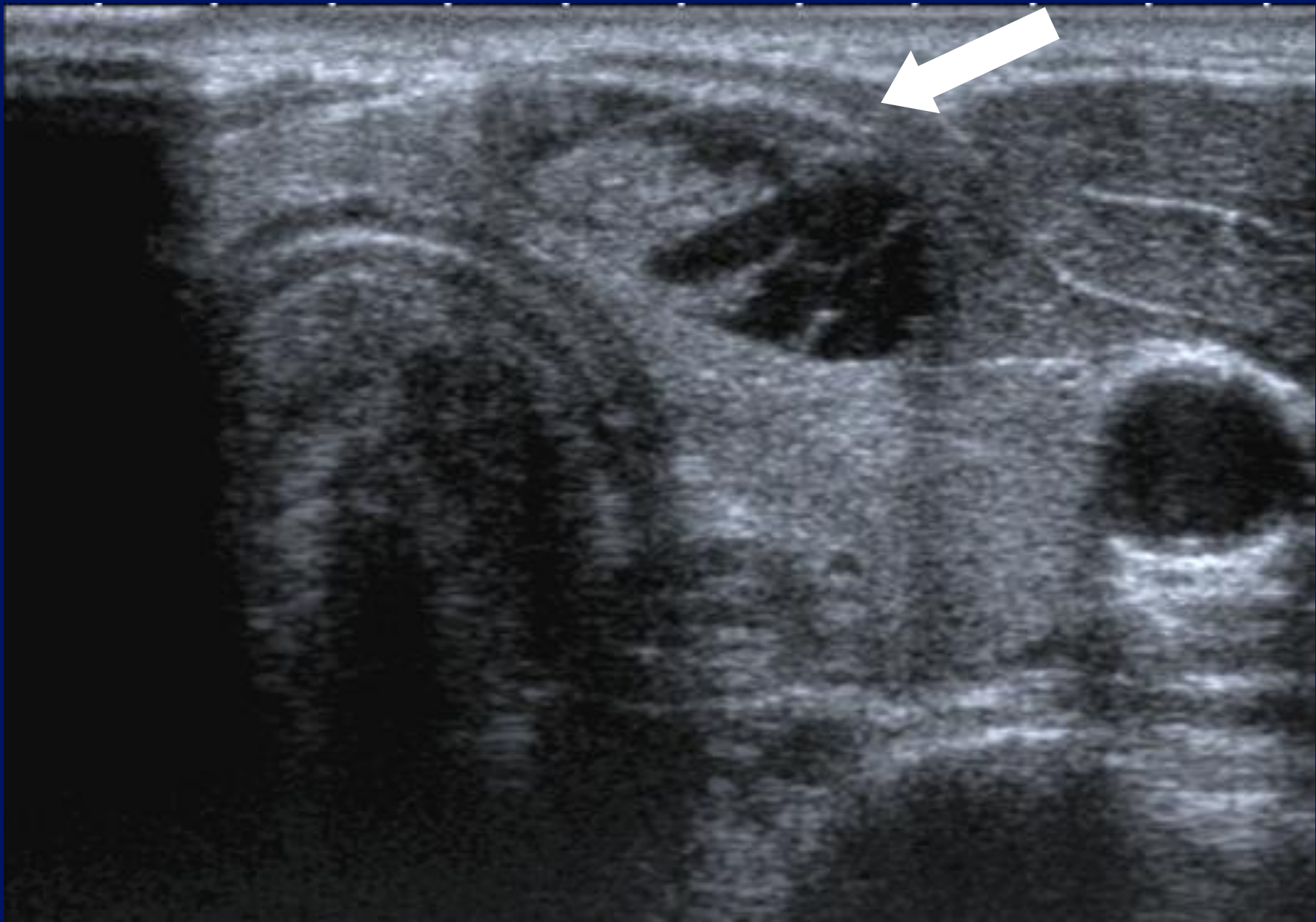
- R Classification.
- Cytological classification(1 -5)
- Clinical scenario.
- Correctly manage patient.

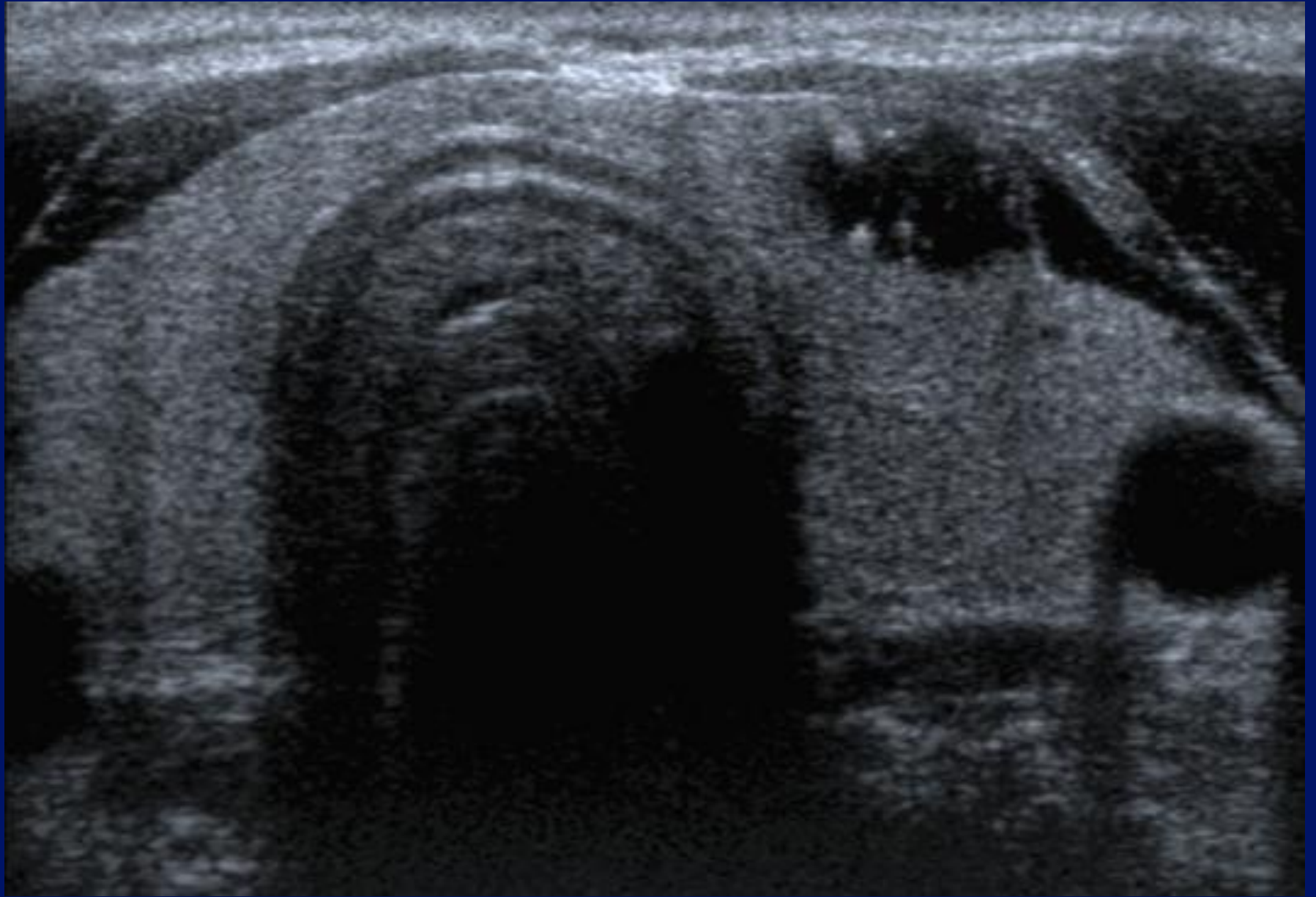
Case 1.

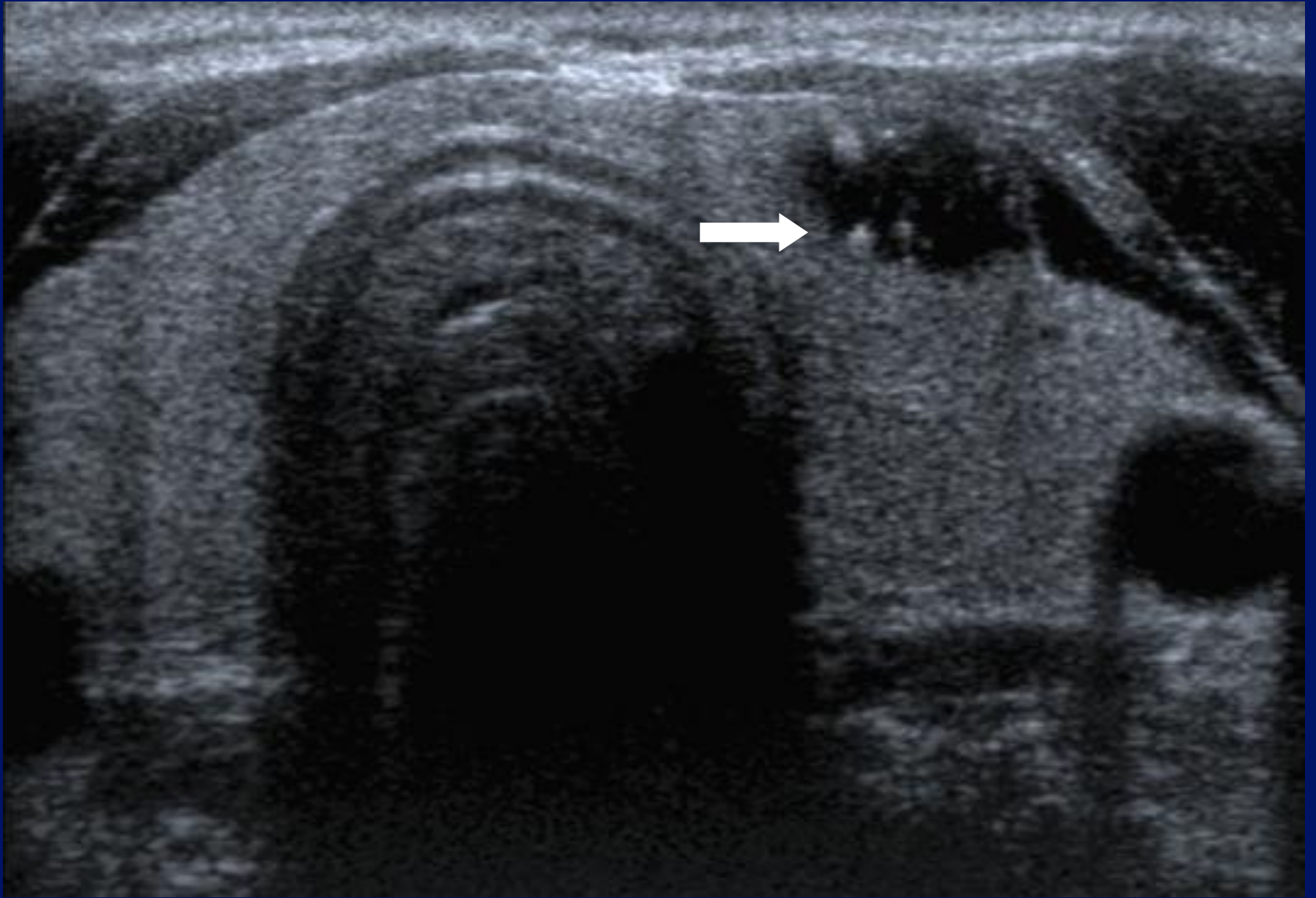


R2

Case 2.







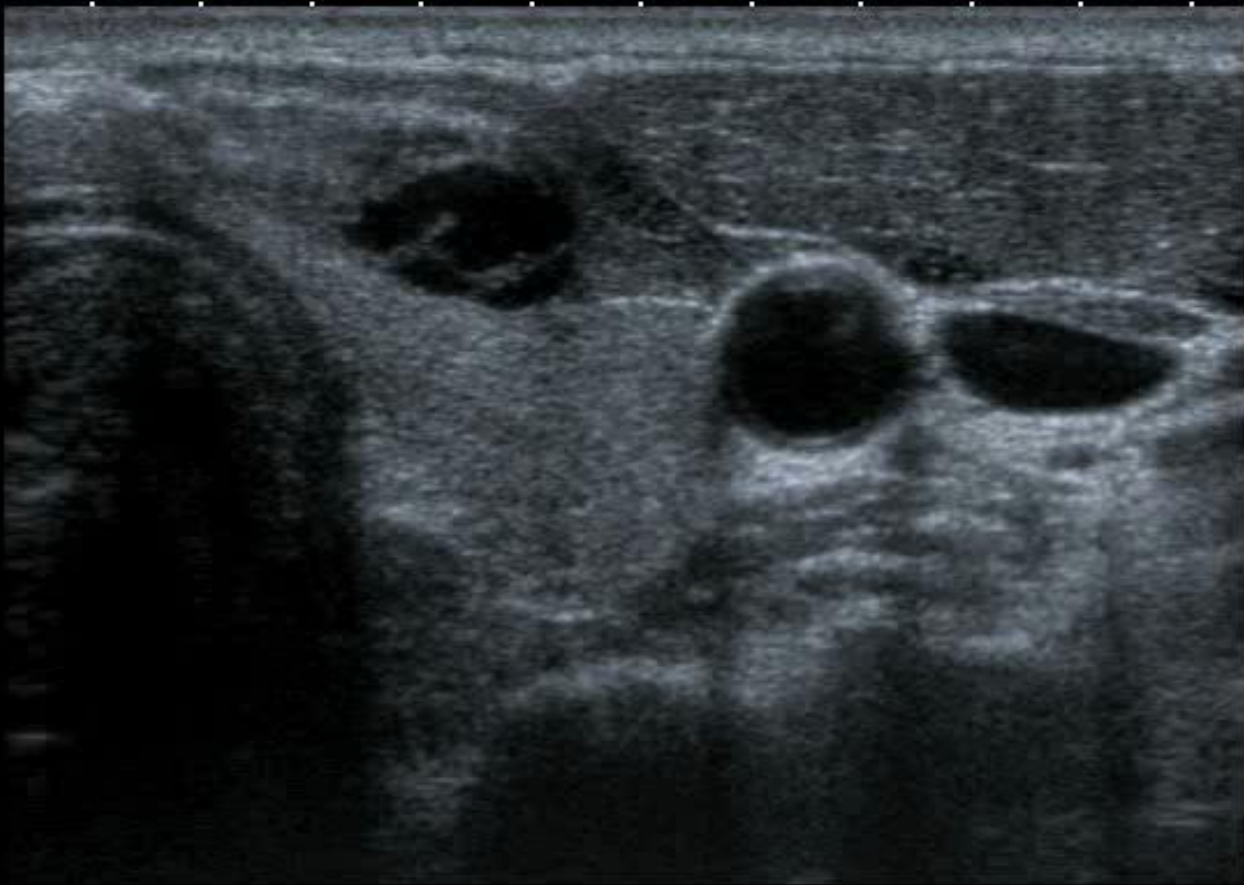
R 2 or 3?



T
0 ◆
1 ◆
2 ◆
3 ◆
4 ◆

12L5
T9.0

33 fps

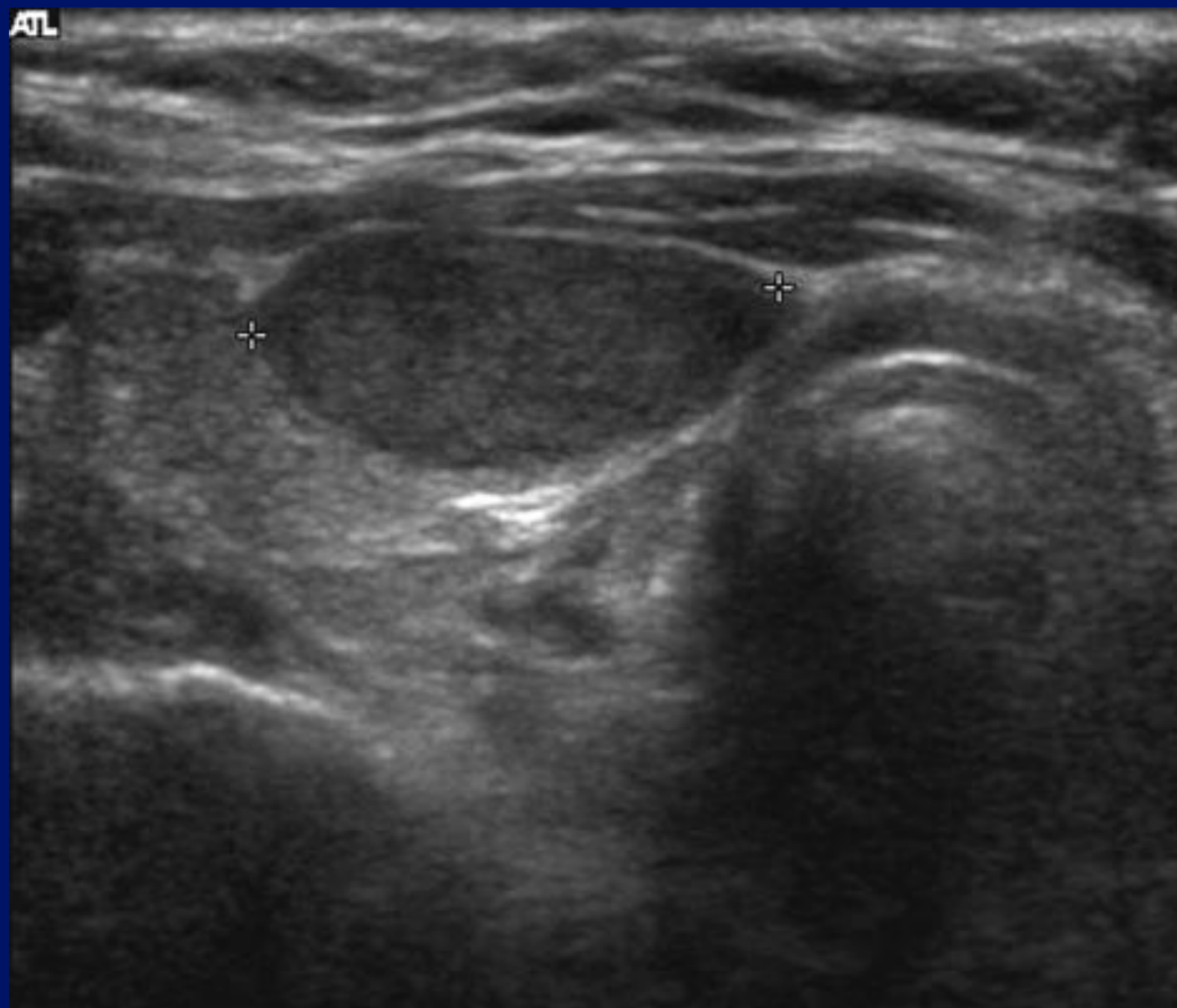


MI:1.6
2DG
93
DR
70

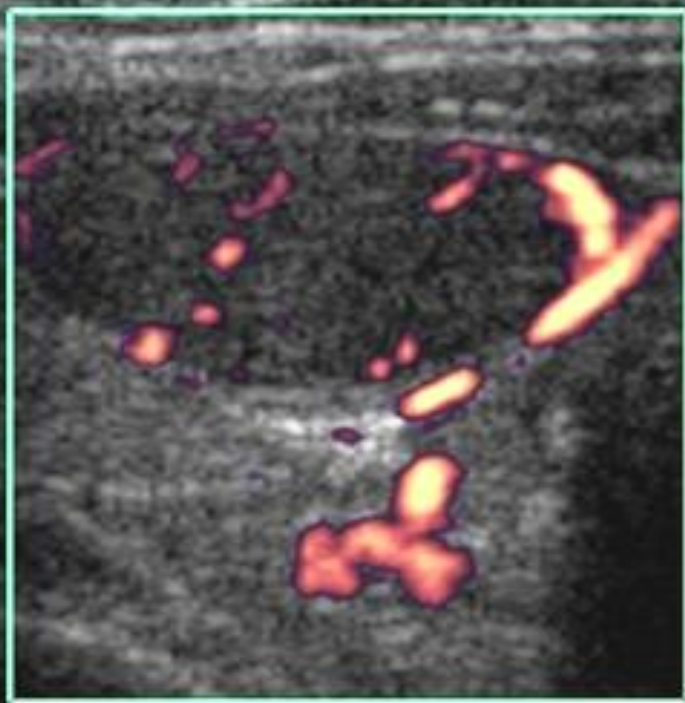


Case 3.

ATL

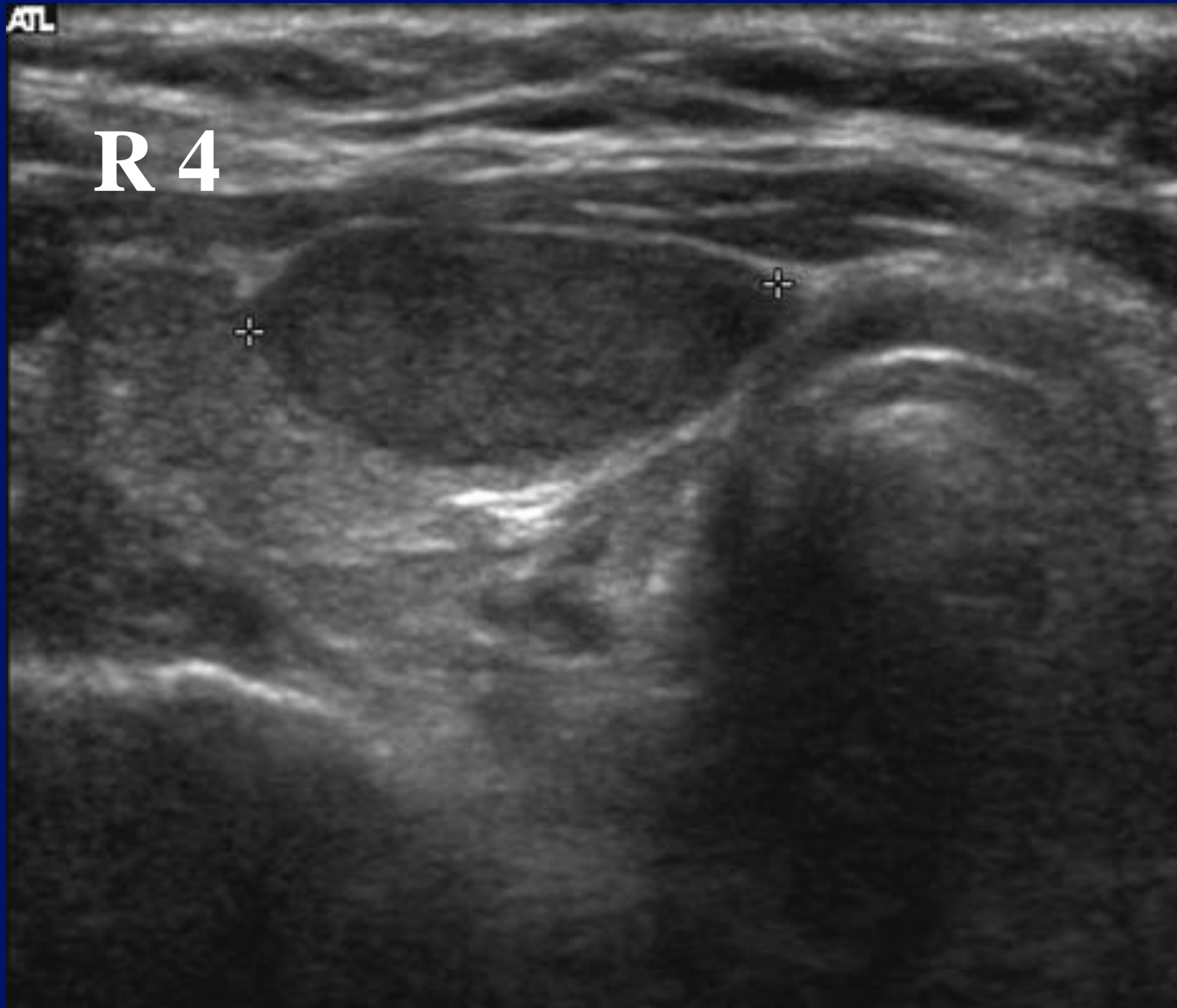

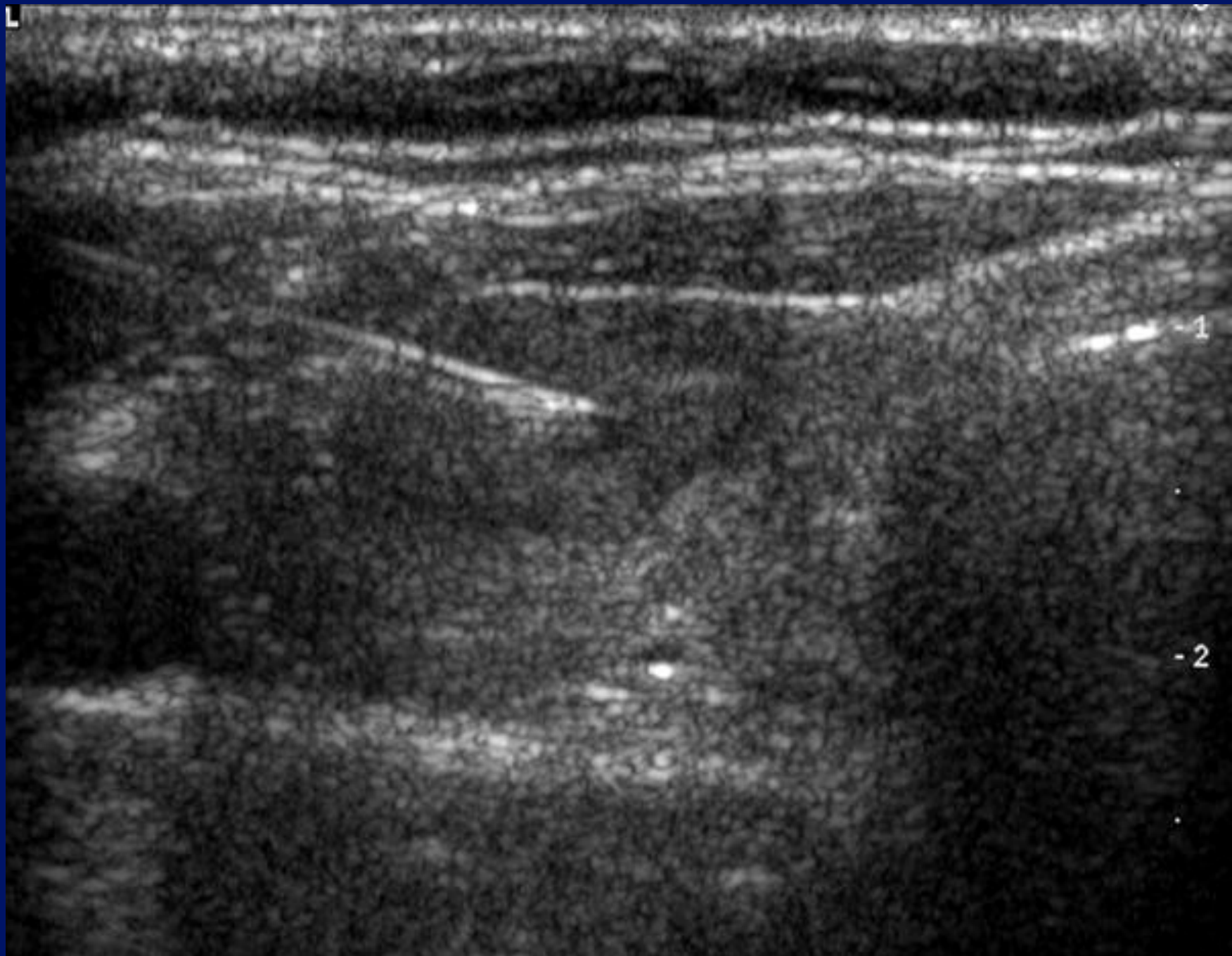
ATL



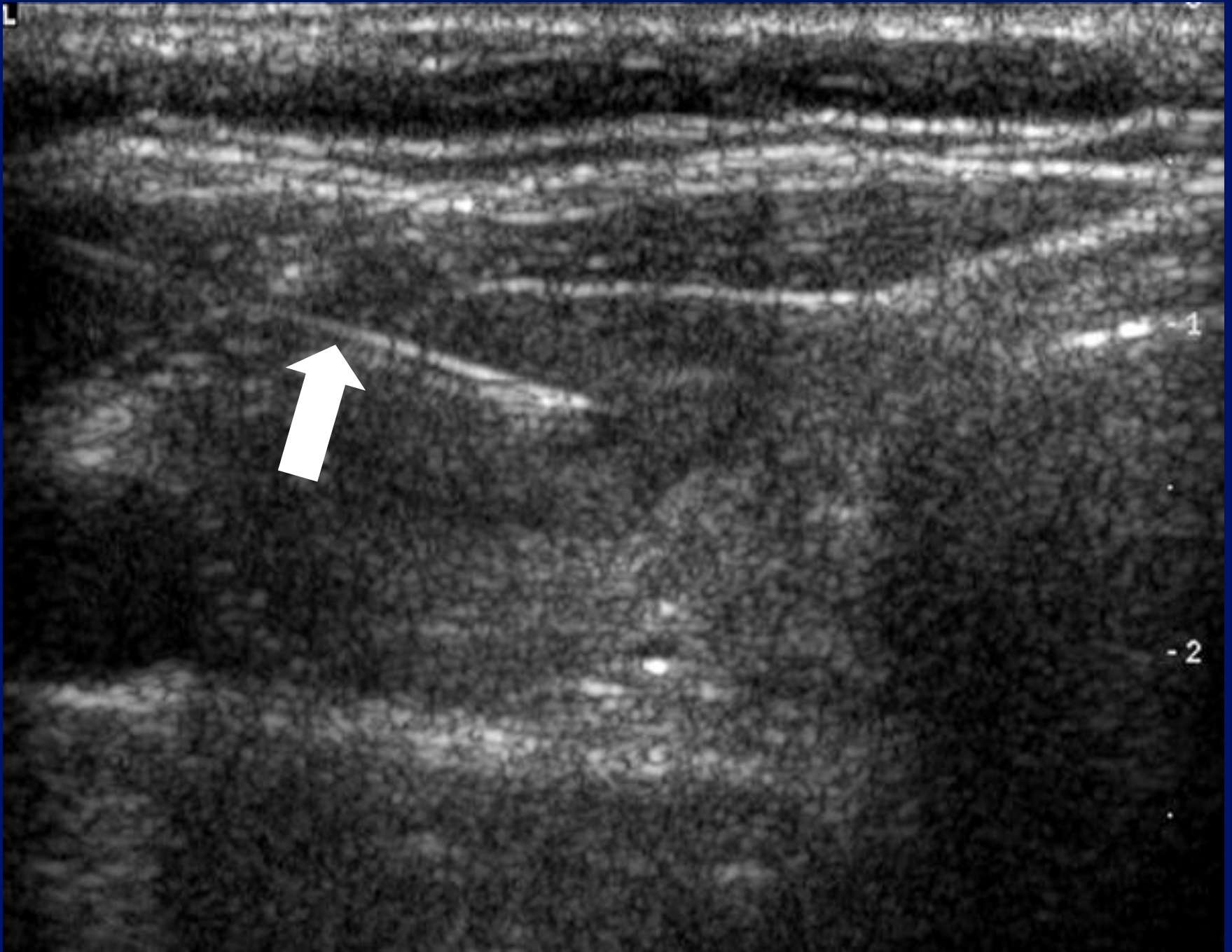
ATL

R 4



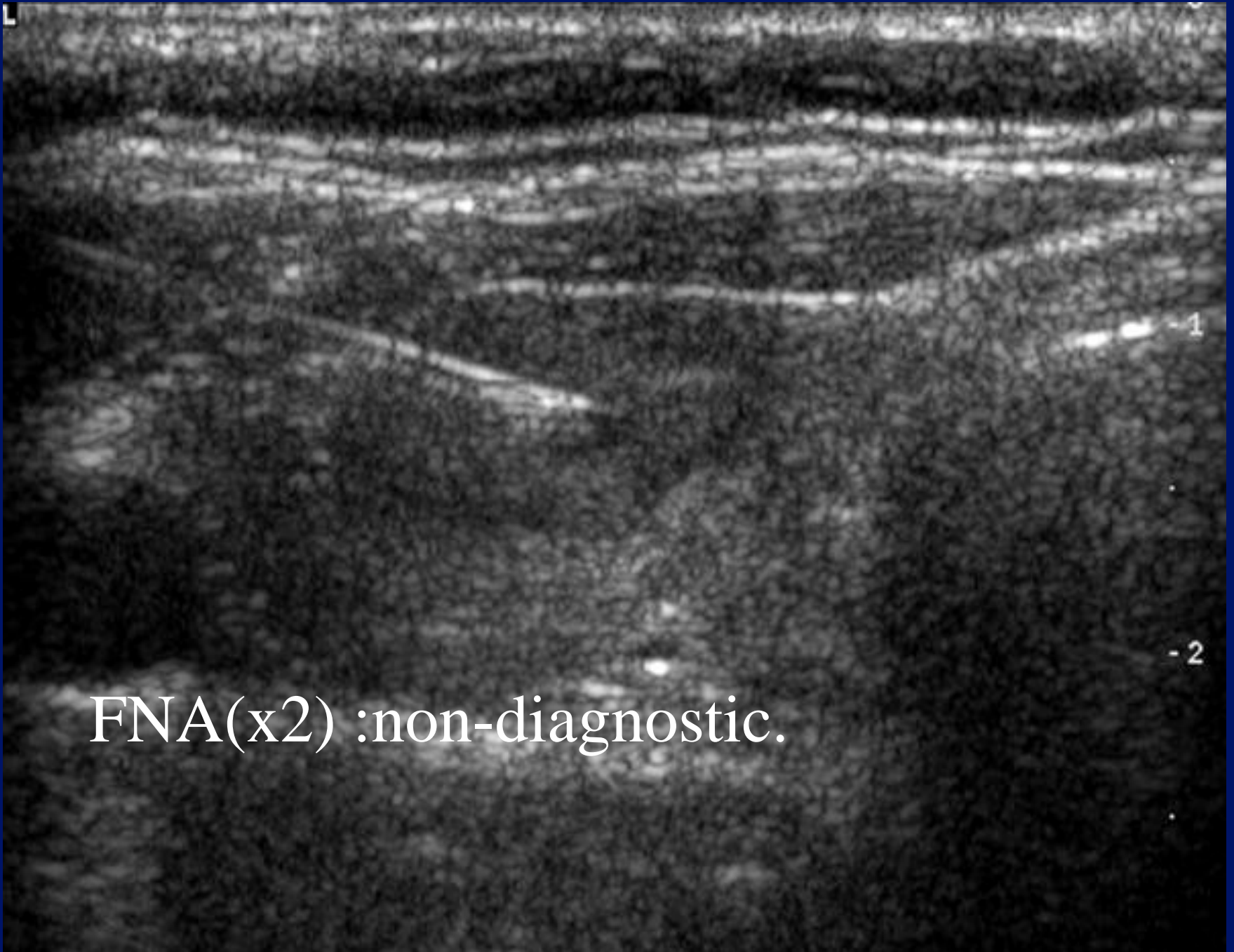


L



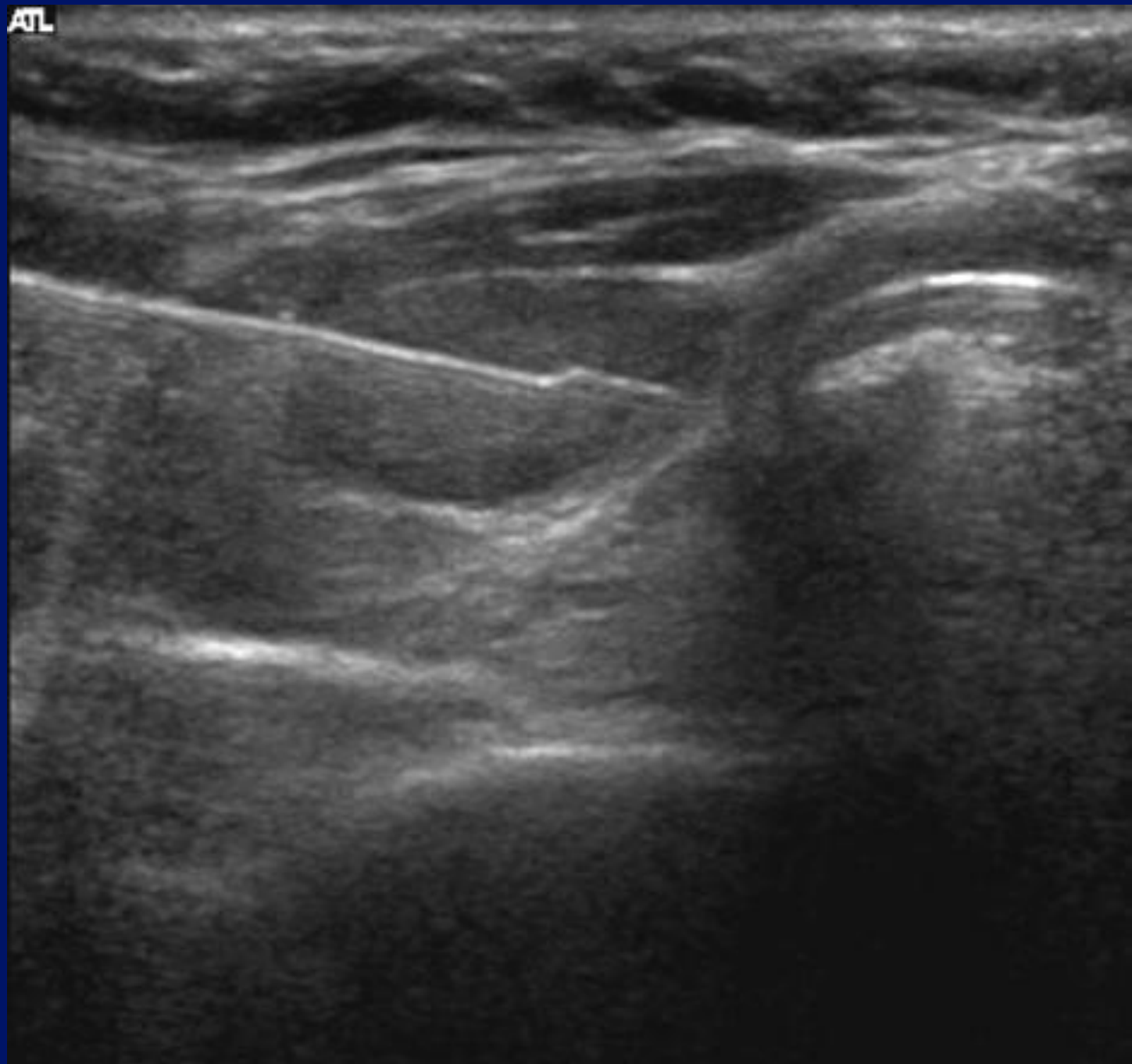
-1

-2

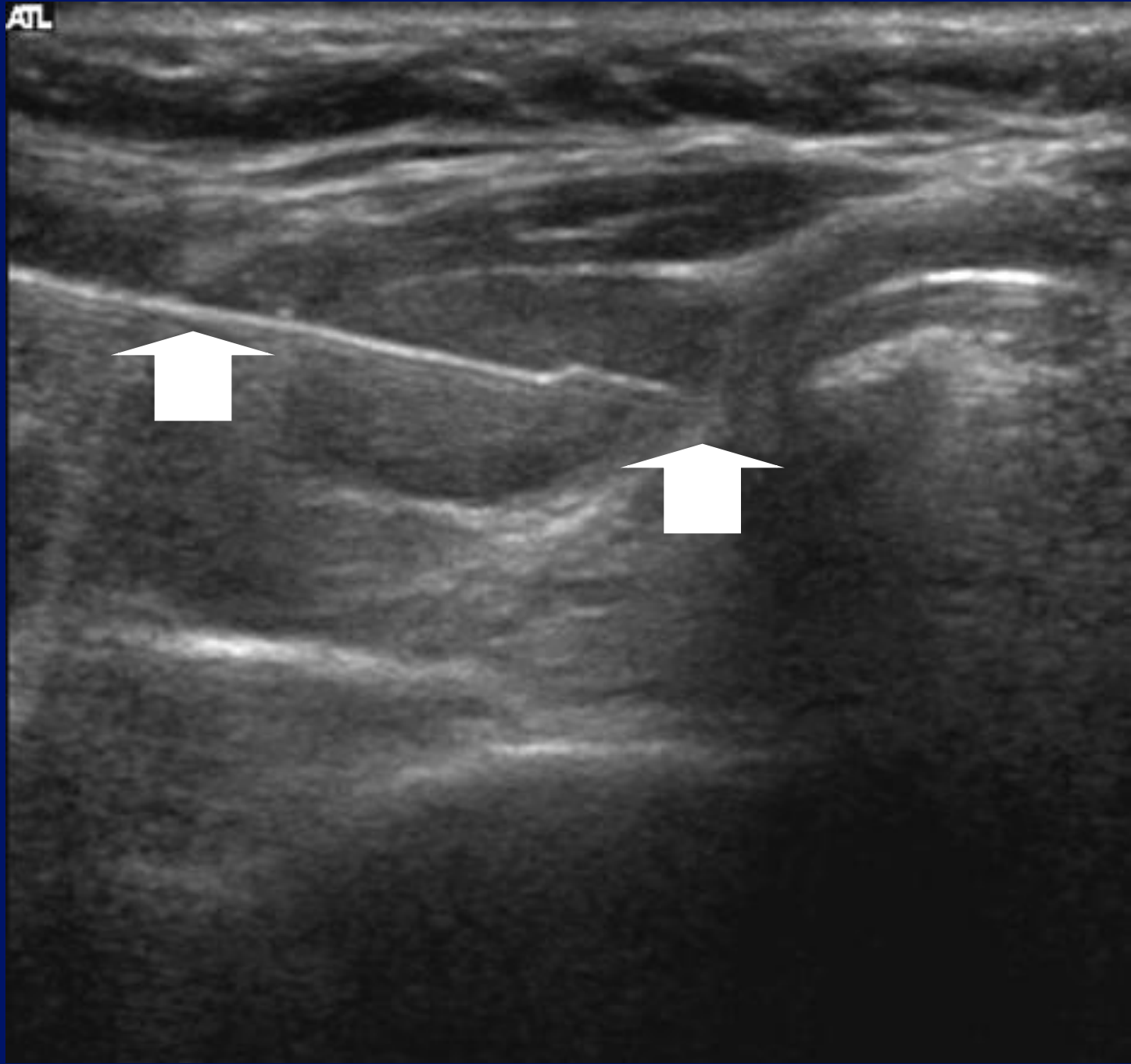


FNA(x2) :non-diagnostic.

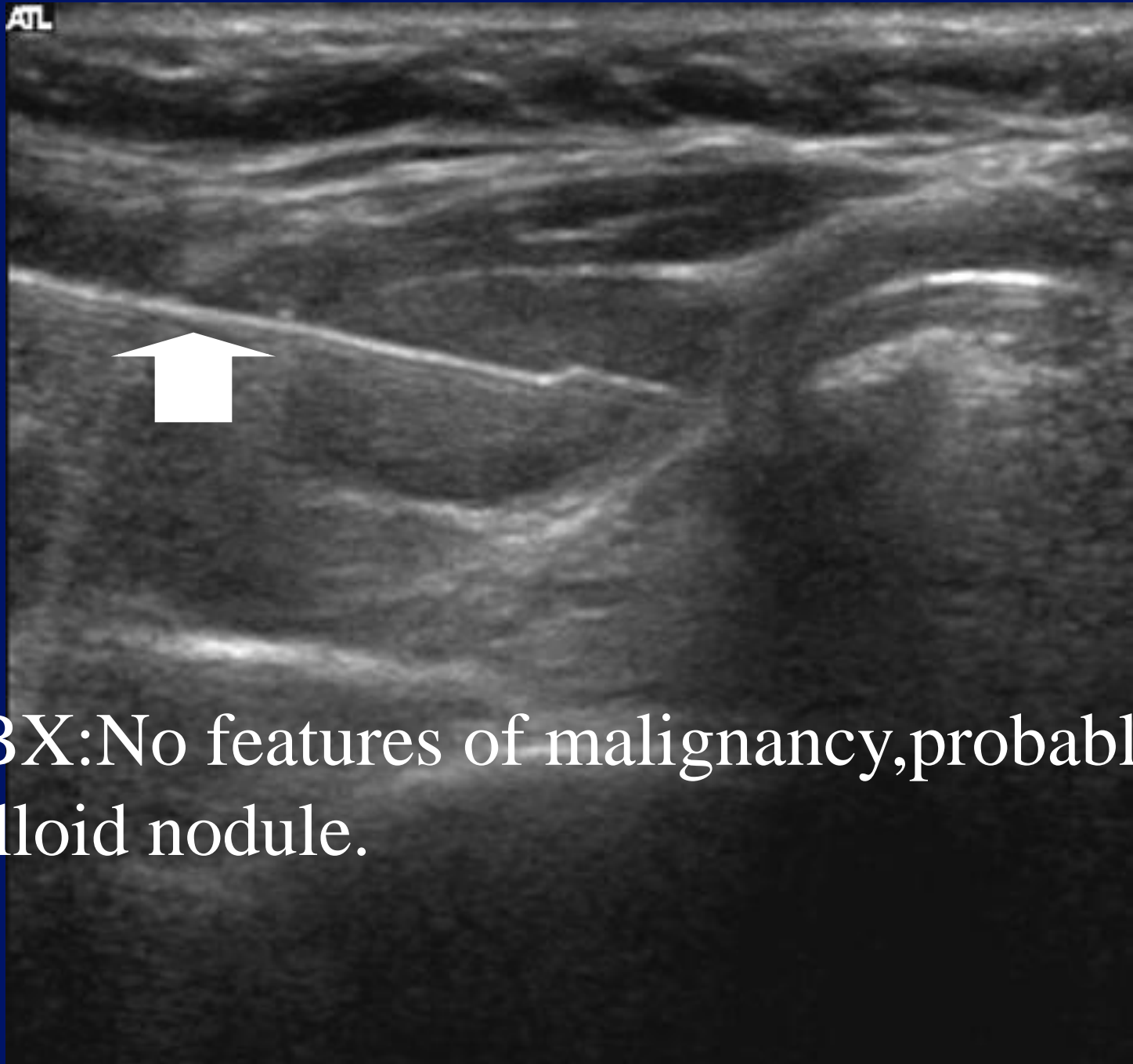ATL



ATL

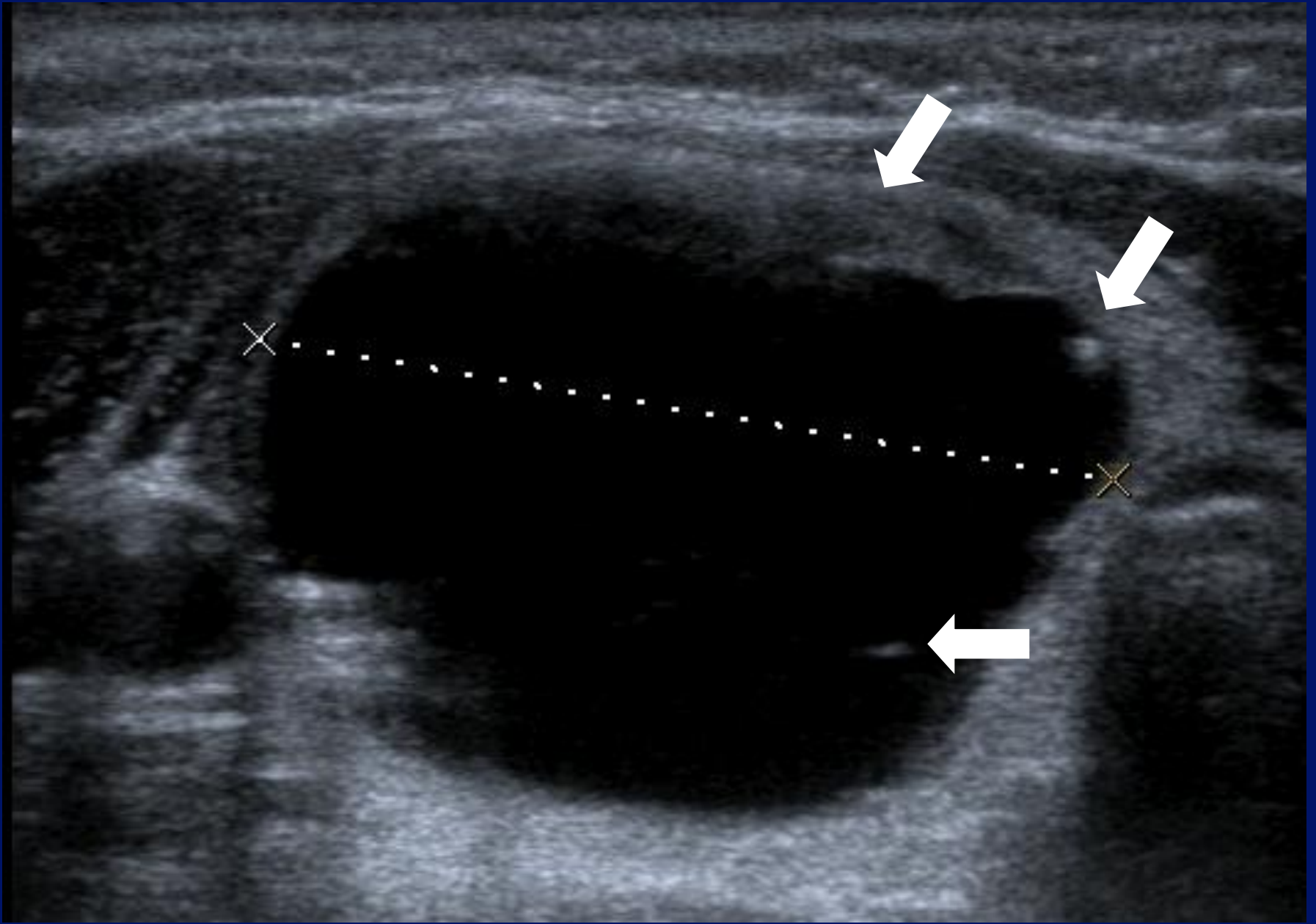


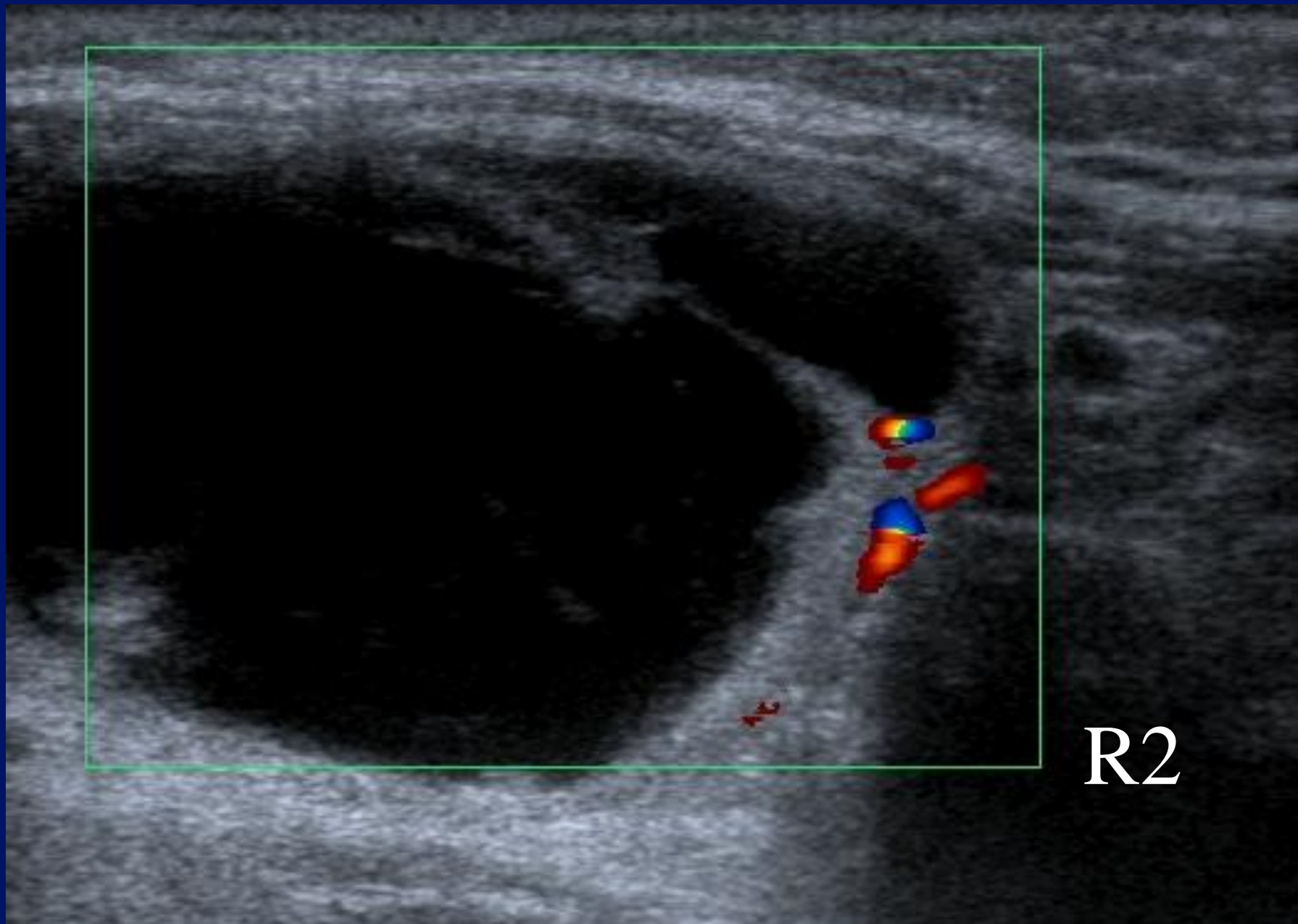
ATL



CBX: No features of malignancy, probable colloid nodule.

Case 4.





R2

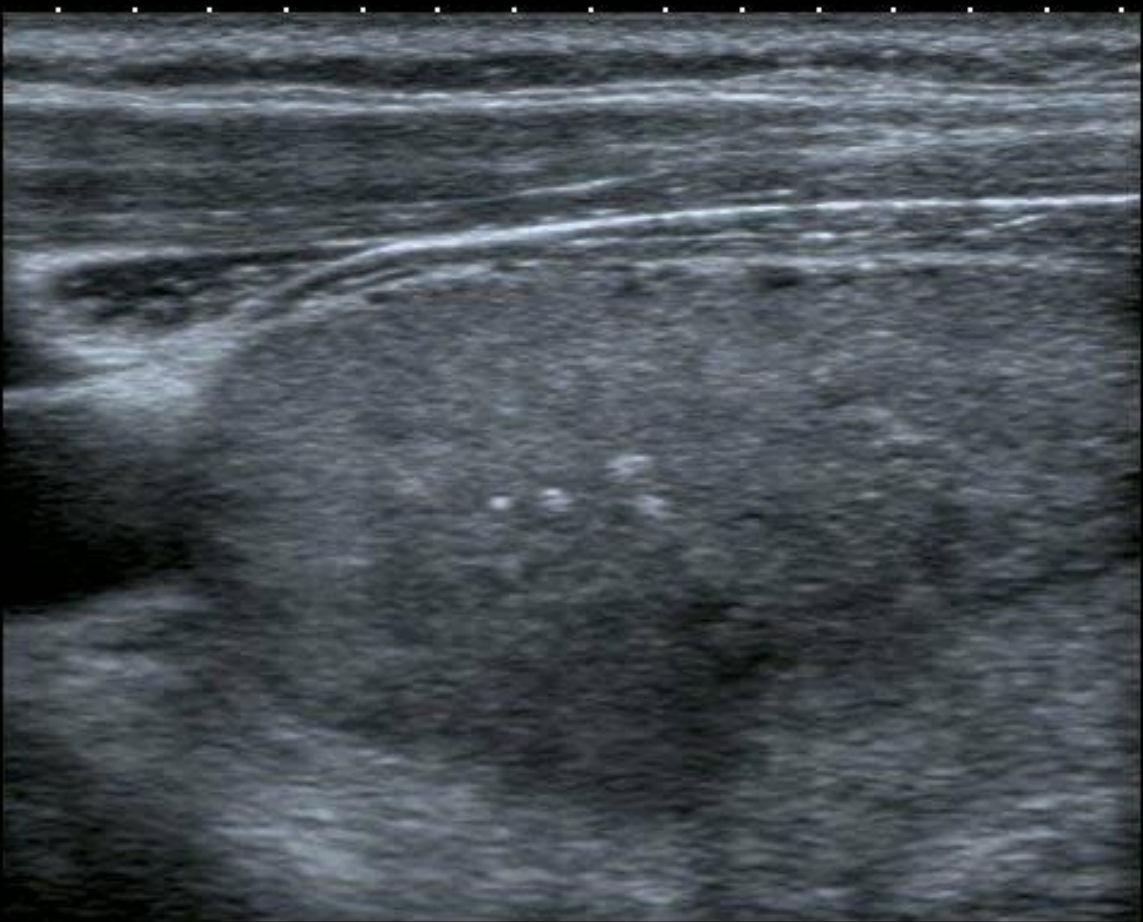Case 5.



R1



- 0 ◆
- 1 ◆▶
- 2 ◆
- 3 ◆



T

14L7
diffT13.0
25 fps

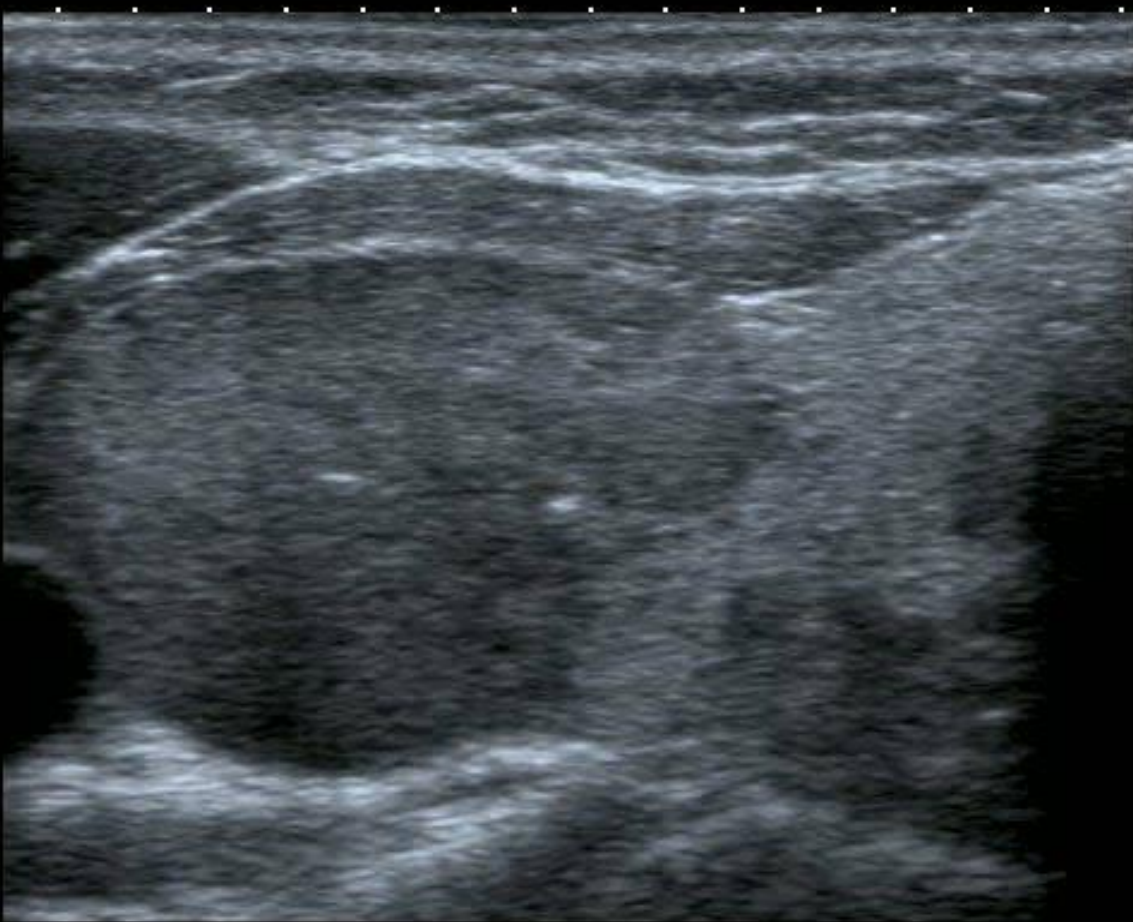
MI: 1.4
2DG
80
DR
65

IP4





- 0 ◆
- 1 ◆▶
- 2 ◆
- 3 ◆



T

14L7
diffT13.0


25 fps


MI: 1.4

2DG
80

DR
65

IP4





© www.aberystwyth.org.uk

www.headandneckultrasound.co.uk

Parathyroid

Parathyroid Adenoma –localisation.

“the only localisation required is to localise an experienced parathyroid surgeon”

Localisation ?

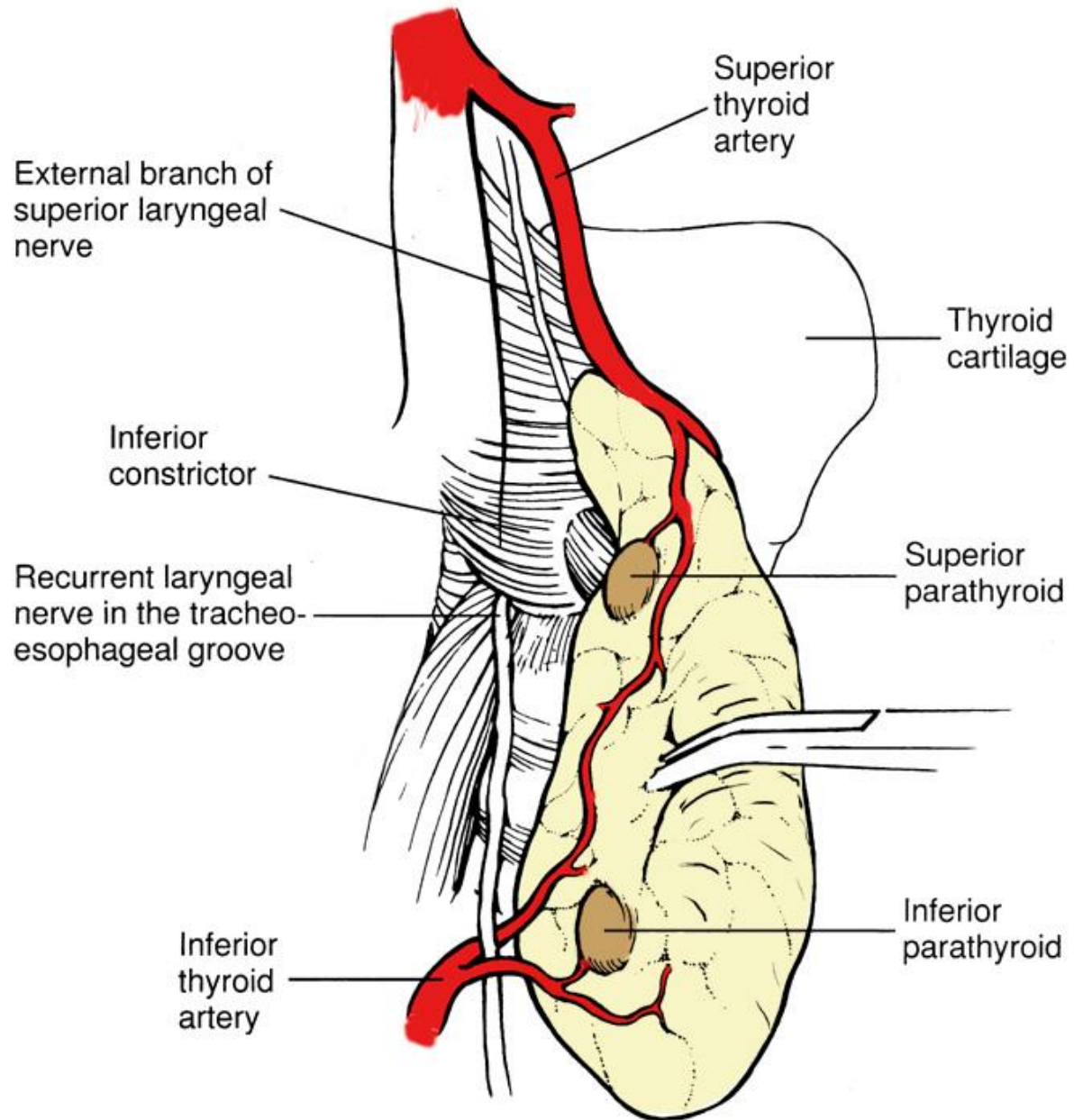
- Unilateral versus bilateral exploration?
- Minimally invasive surgery.
- Day case parathyroidectomy.
- Excision under local anaesthesia.

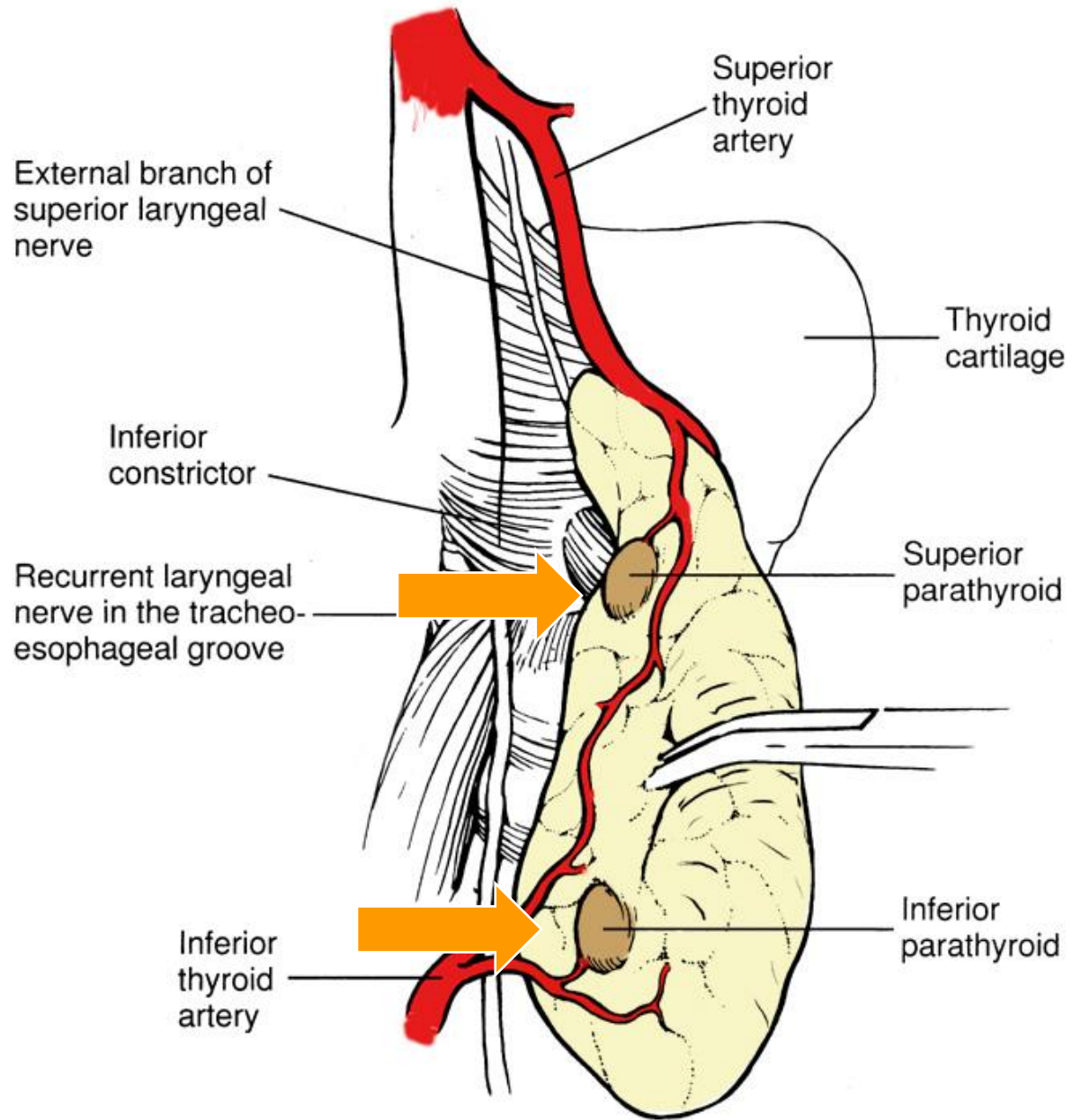
Localisation - patient.

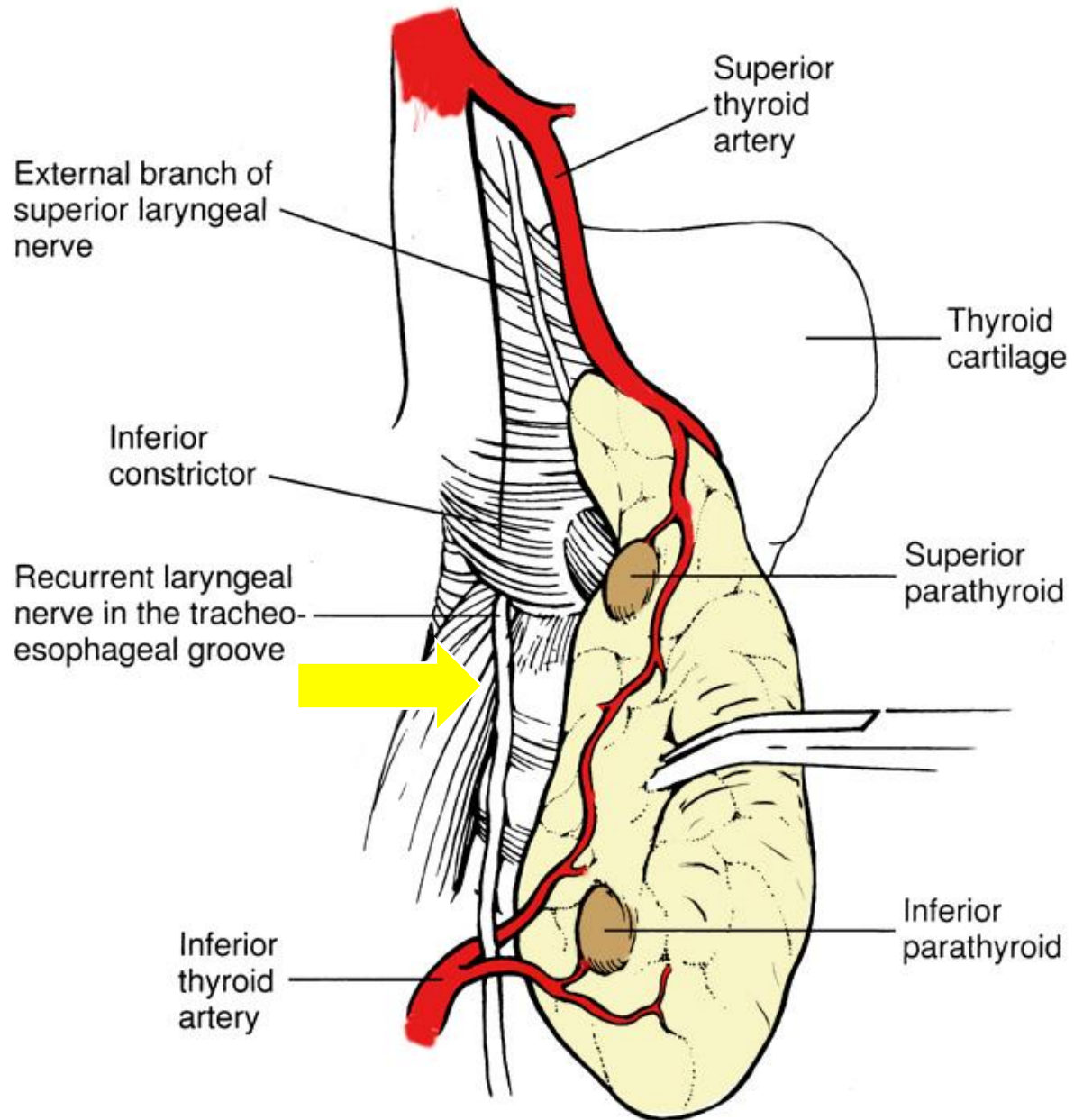
- Reduce operating time.
- Decrease in post surgical complications.
- Safer and more cost effective procedure.

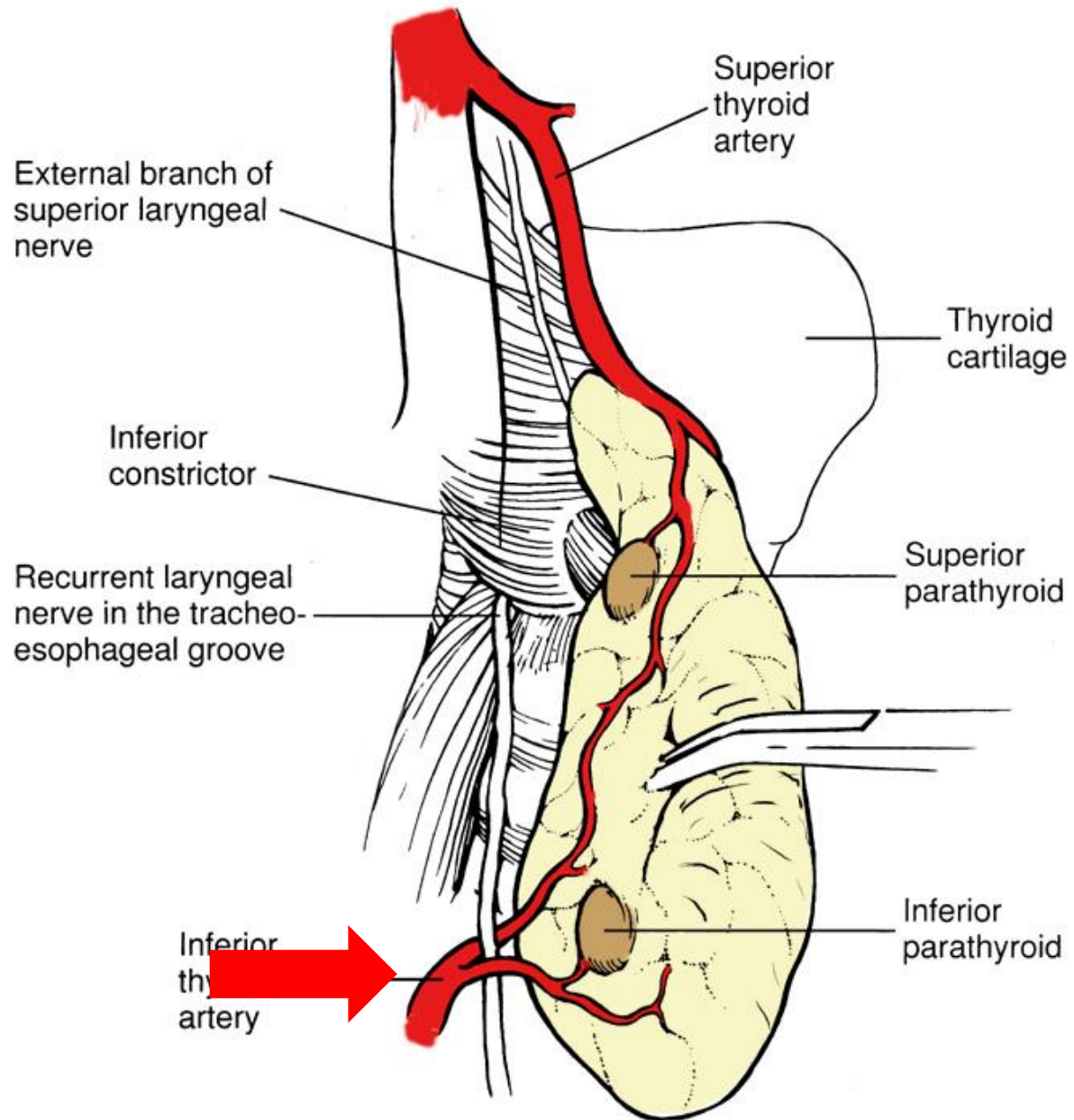
Parathyroid localisation.

- Problem?
- Unpredictability of anatomy.









Anatomy.

- 91% have 4 glands.
- 4% have 3 glands.
- 5% have 5 glands.
- (0.6% have six glands.)

Anatomical variation .



- Embryology!



Embryology – Superior Parathyroid.


- Superior parathyroid derives from 4th branchial pouch-lateral thyroid/C cell complex .
- Postero-lateral superior (mid)pole.
- Short embryological path – fairly constant anatomy.


Embryology – inferior parathyroid..



- Inferior gland – third branchial pouch.
- Descends with the thymus.
- Longer embryological route – more varied position.
- May lie within the fat of the thyro-thymic horn.
- Inferior parathyroids are likely to be intra-thyroid (not superior)


















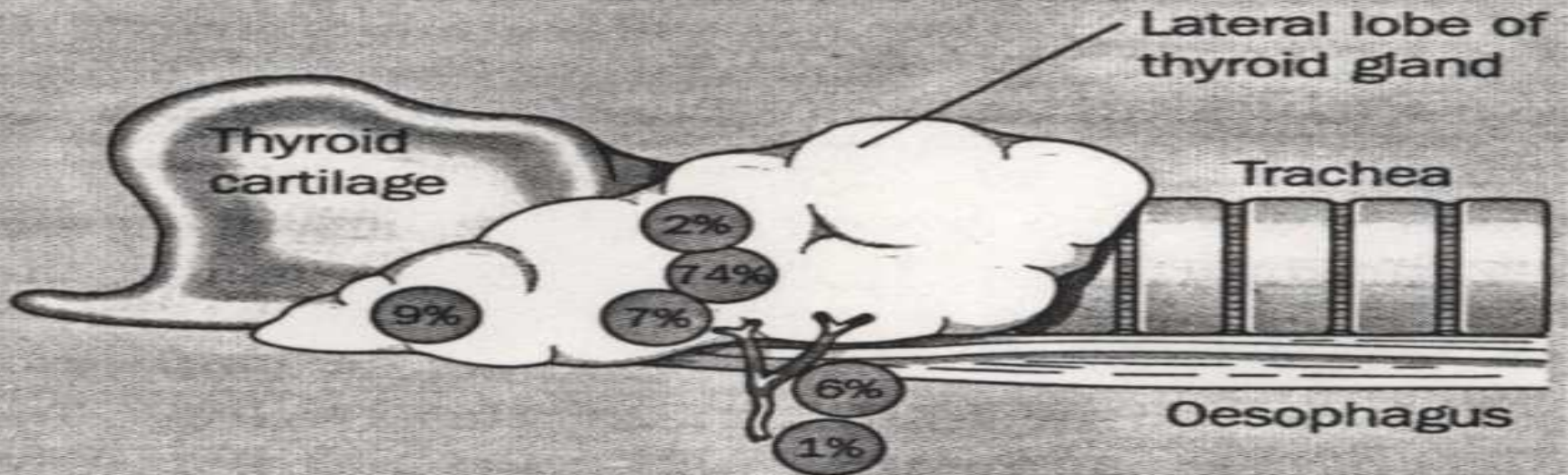




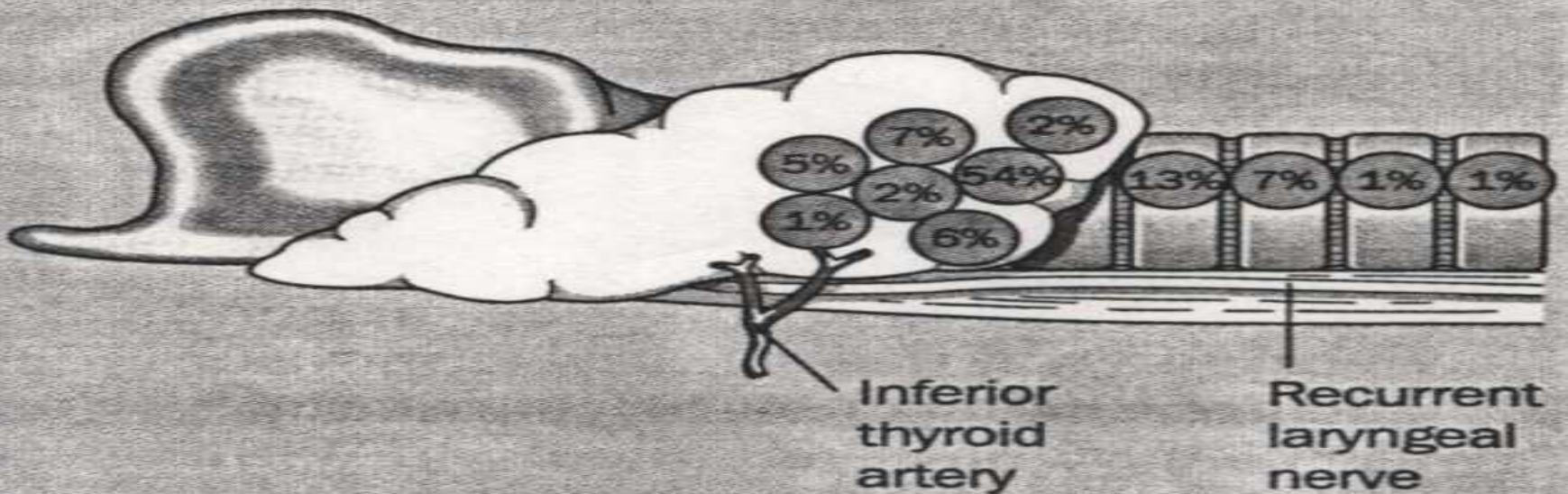




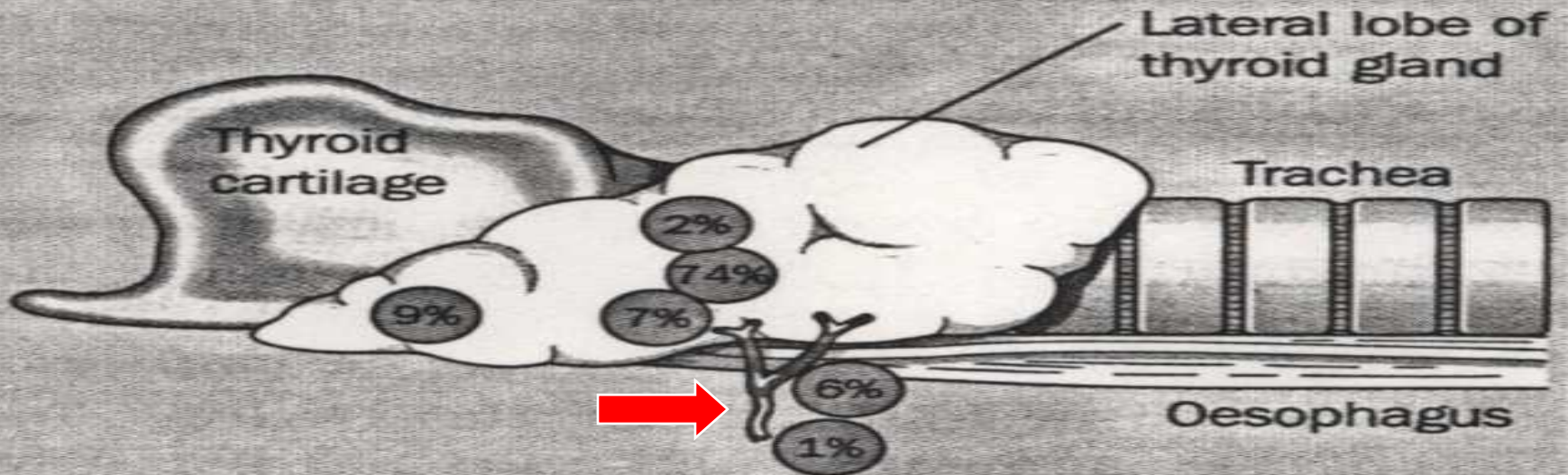
Superior parathyroid gland



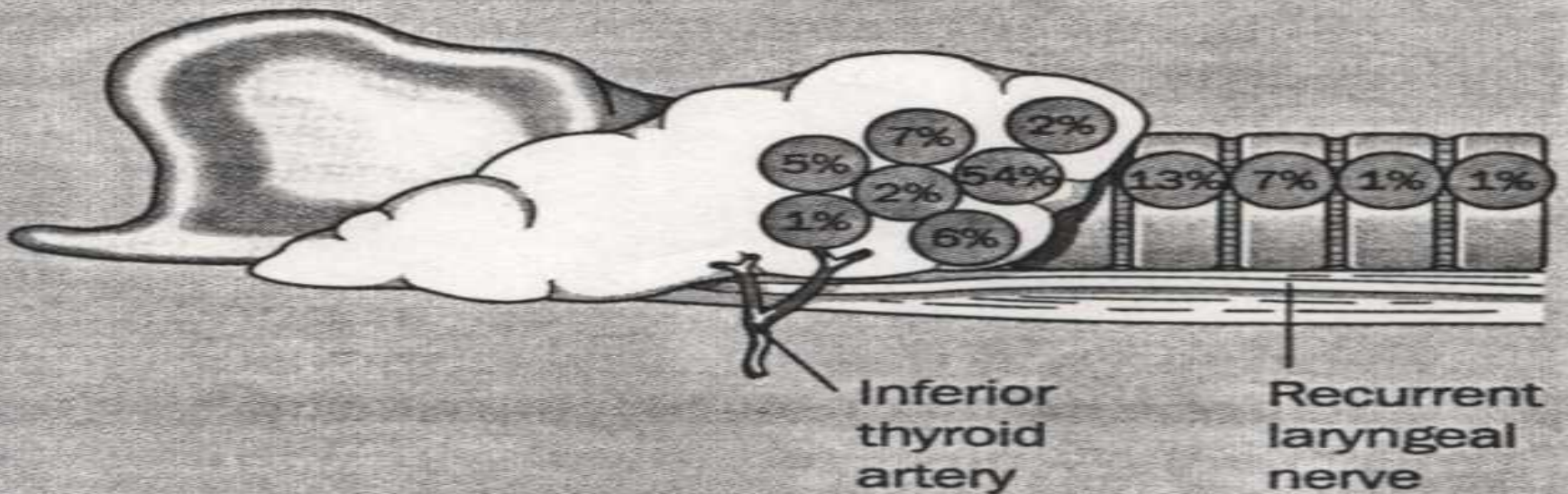
Inferior parathyroid gland



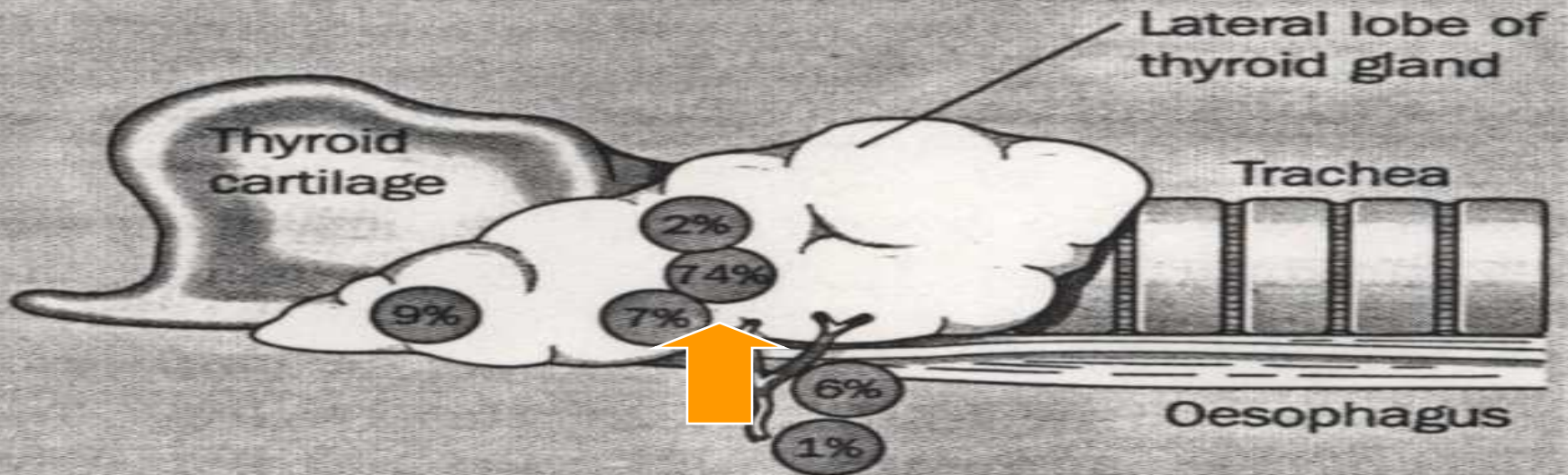
Superior parathyroid gland



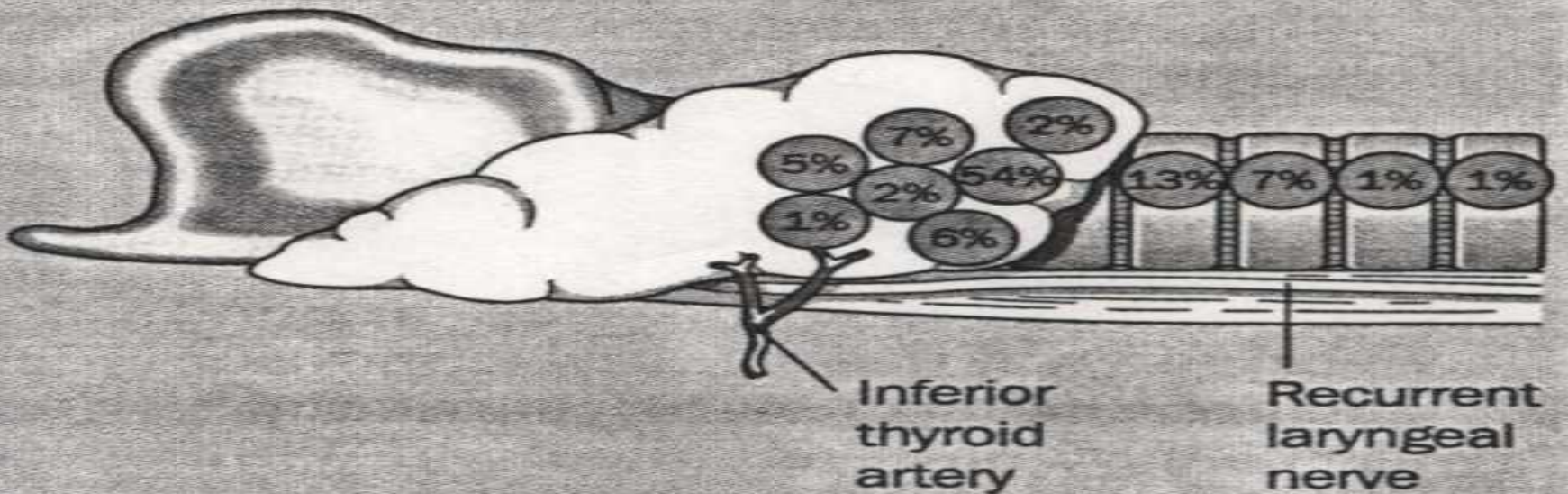
Inferior parathyroid gland



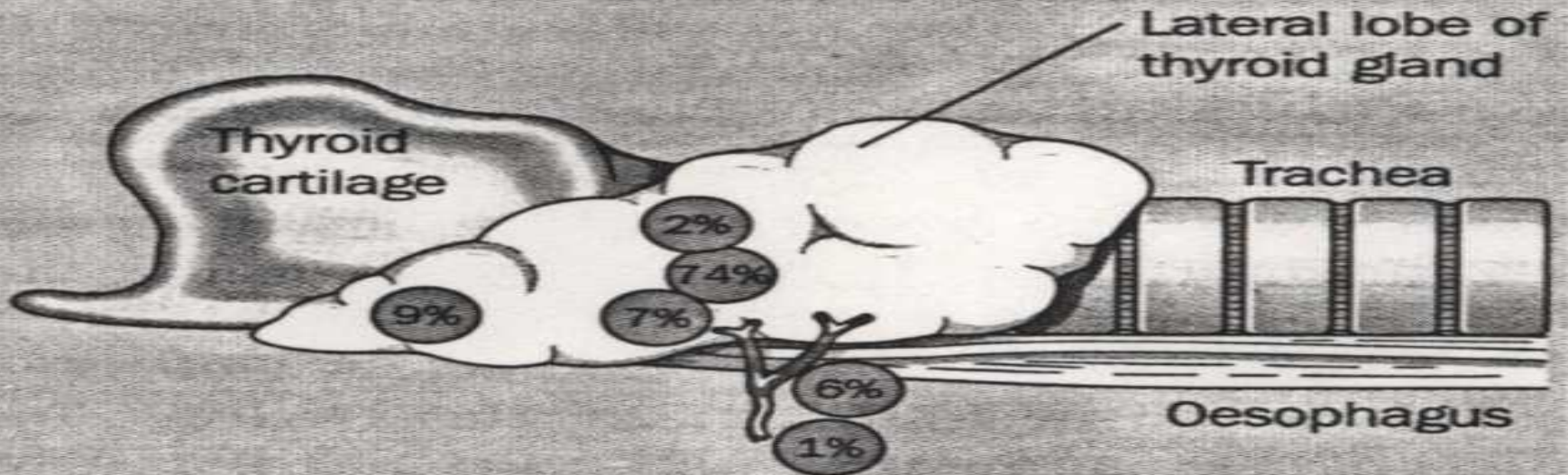
Superior parathyroid gland



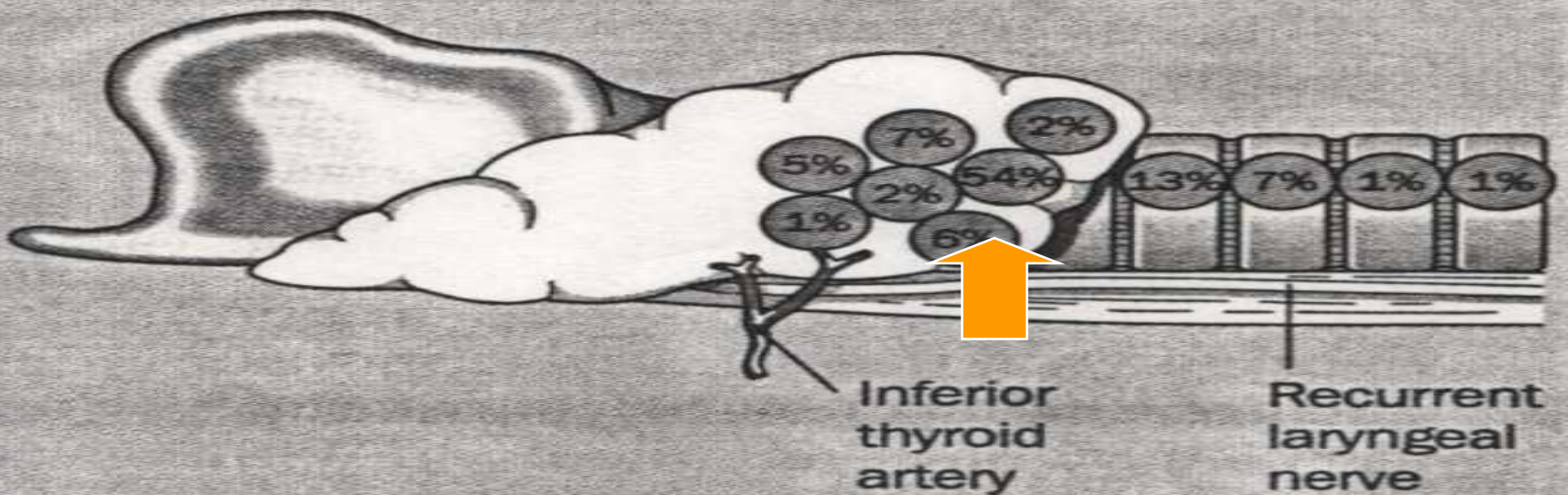
Inferior parathyroid gland



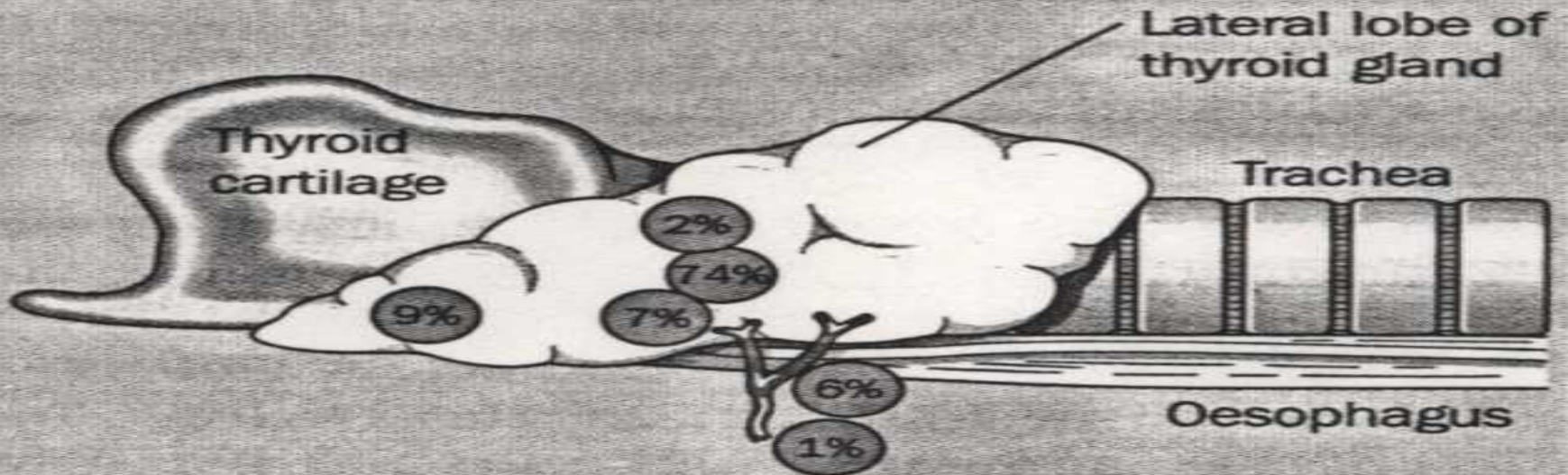
Superior parathyroid gland



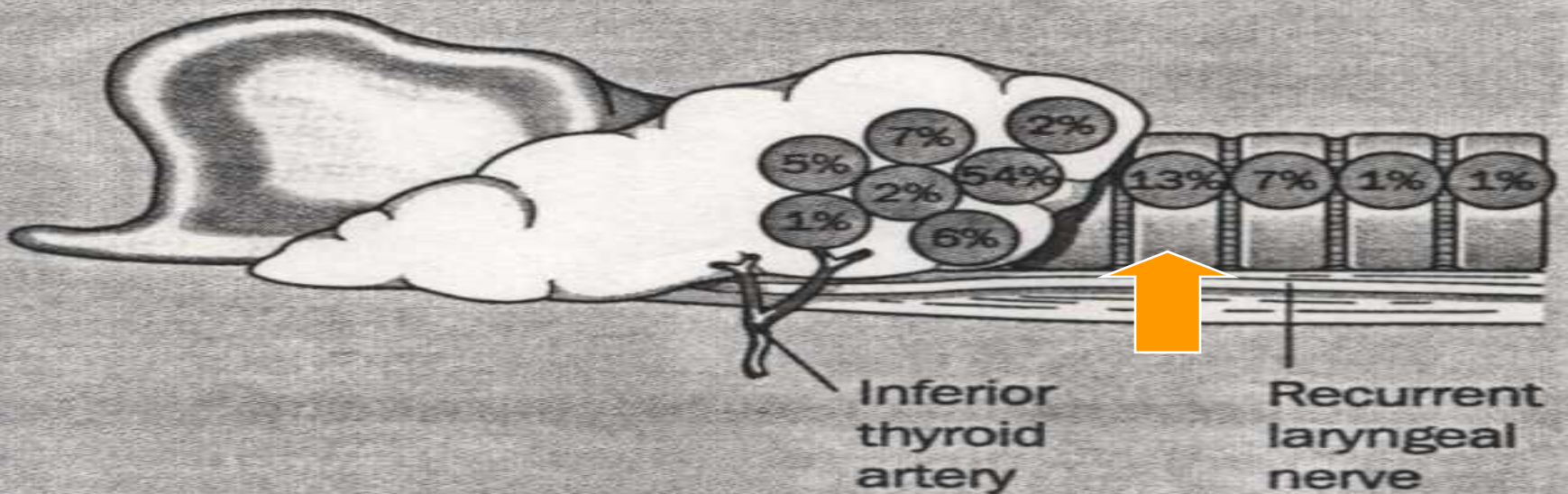
Inferior parathyroid gland



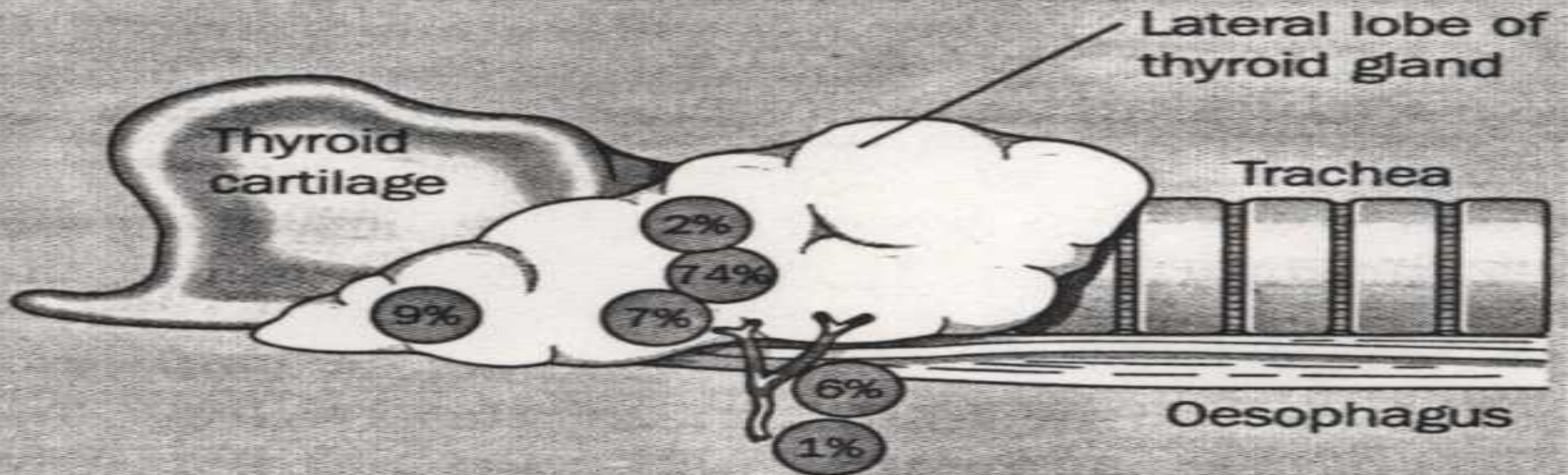
Superior parathyroid gland



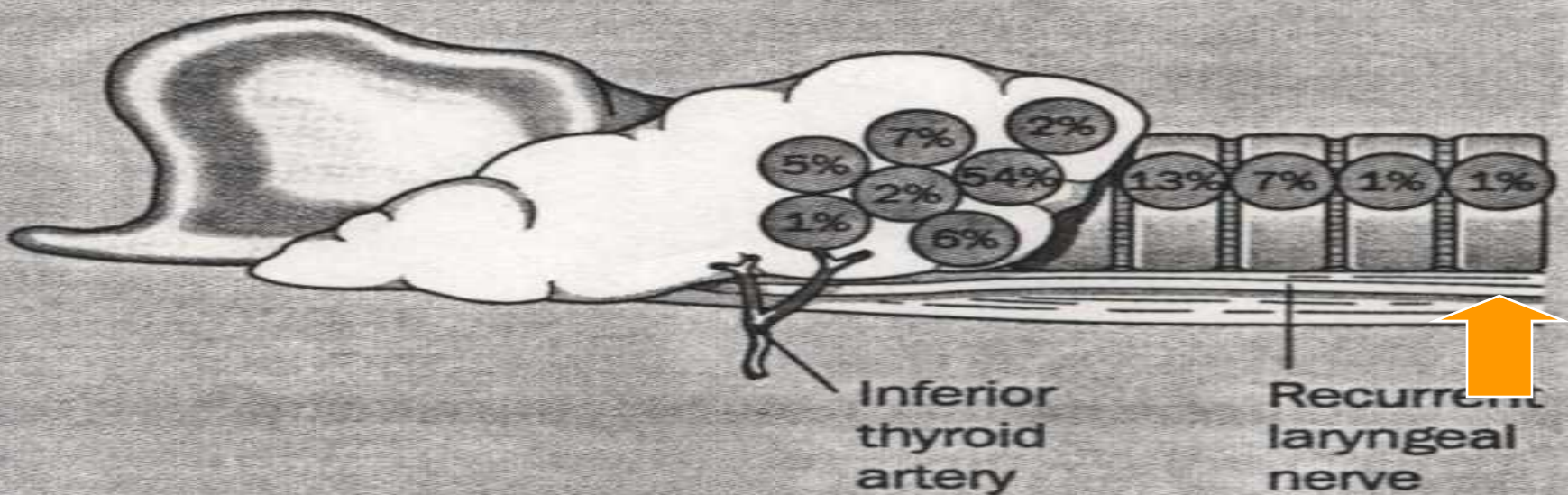
Inferior parathyroid gland

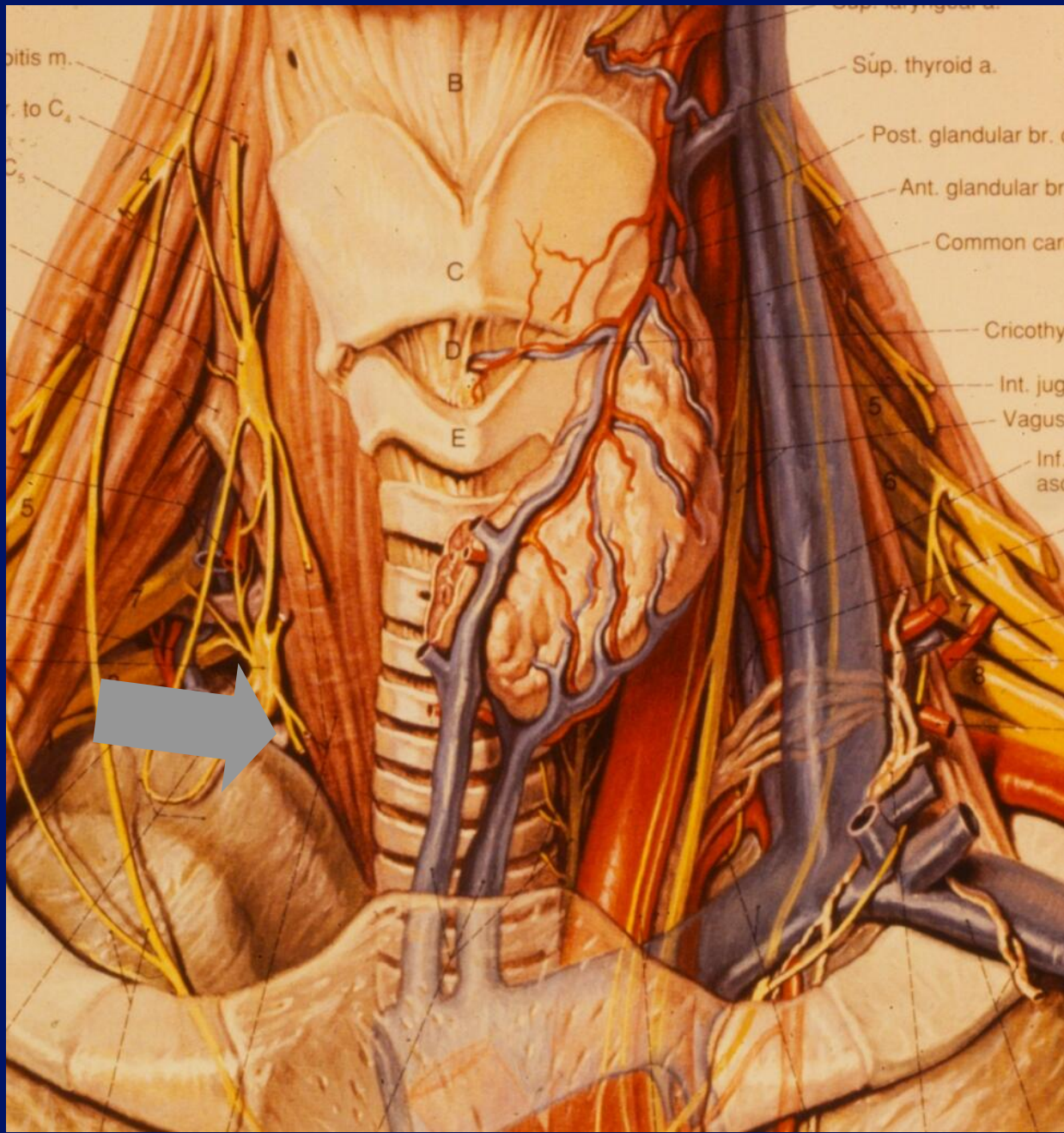

Superior parathyroid gland



Inferior parathyroid gland





bitis m.

r. to C₄

C₅

5

B

C

D

E

Súp. thyroid a.

Post. glandular br.

Ant. glandular br

Common car

Cricothy

Int. jug

Vagus

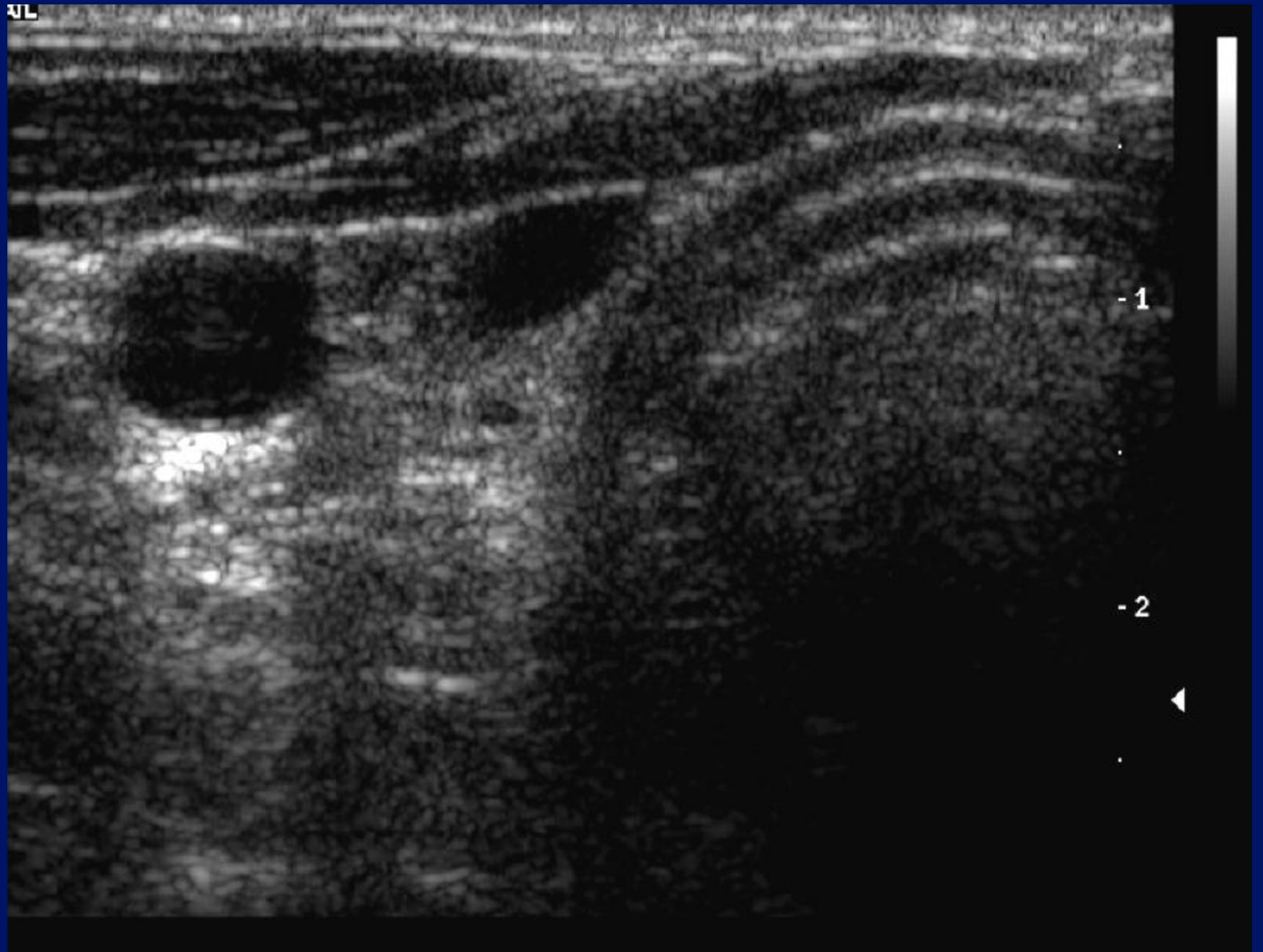
Inf. asc

5

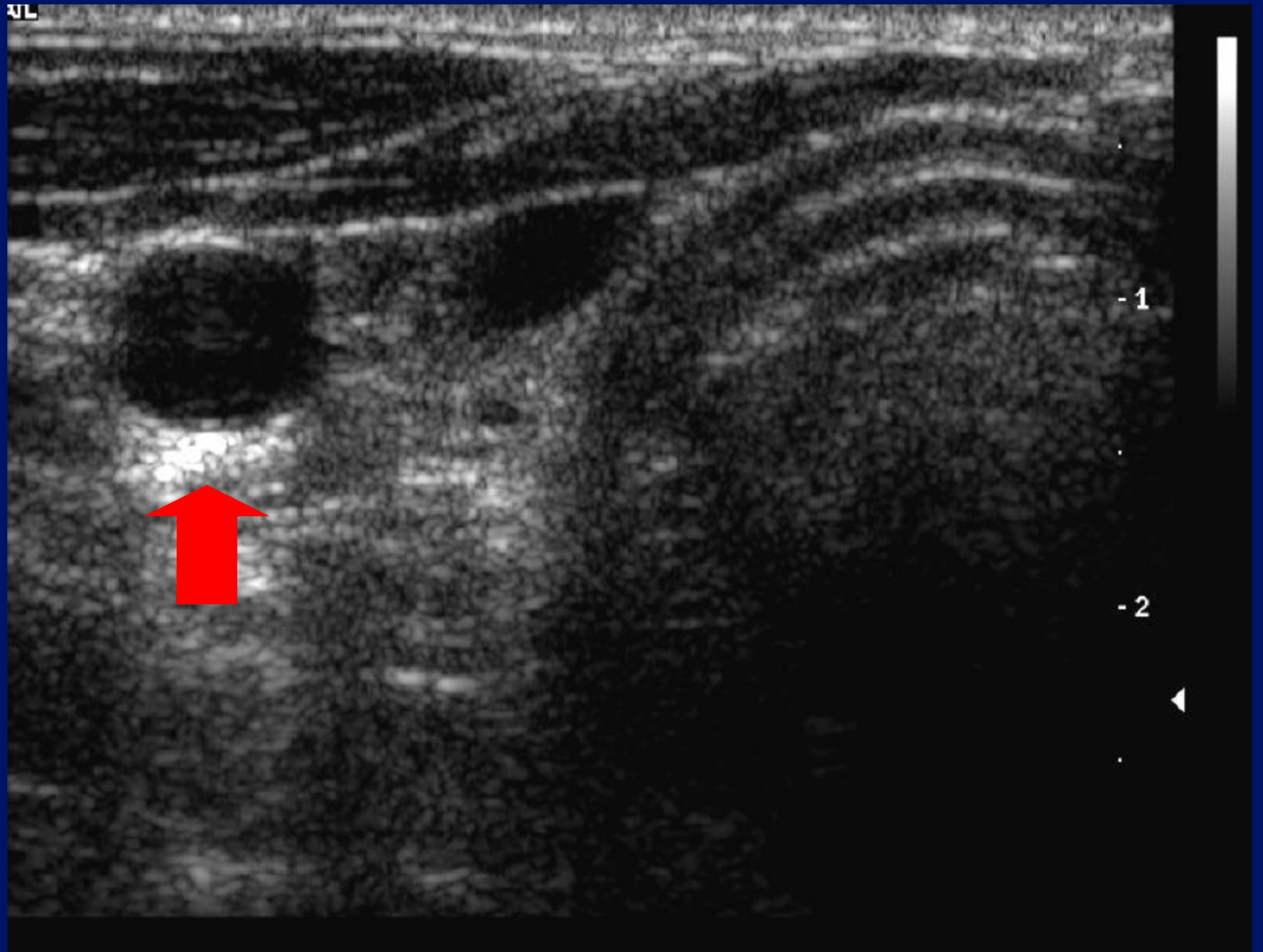
6

8

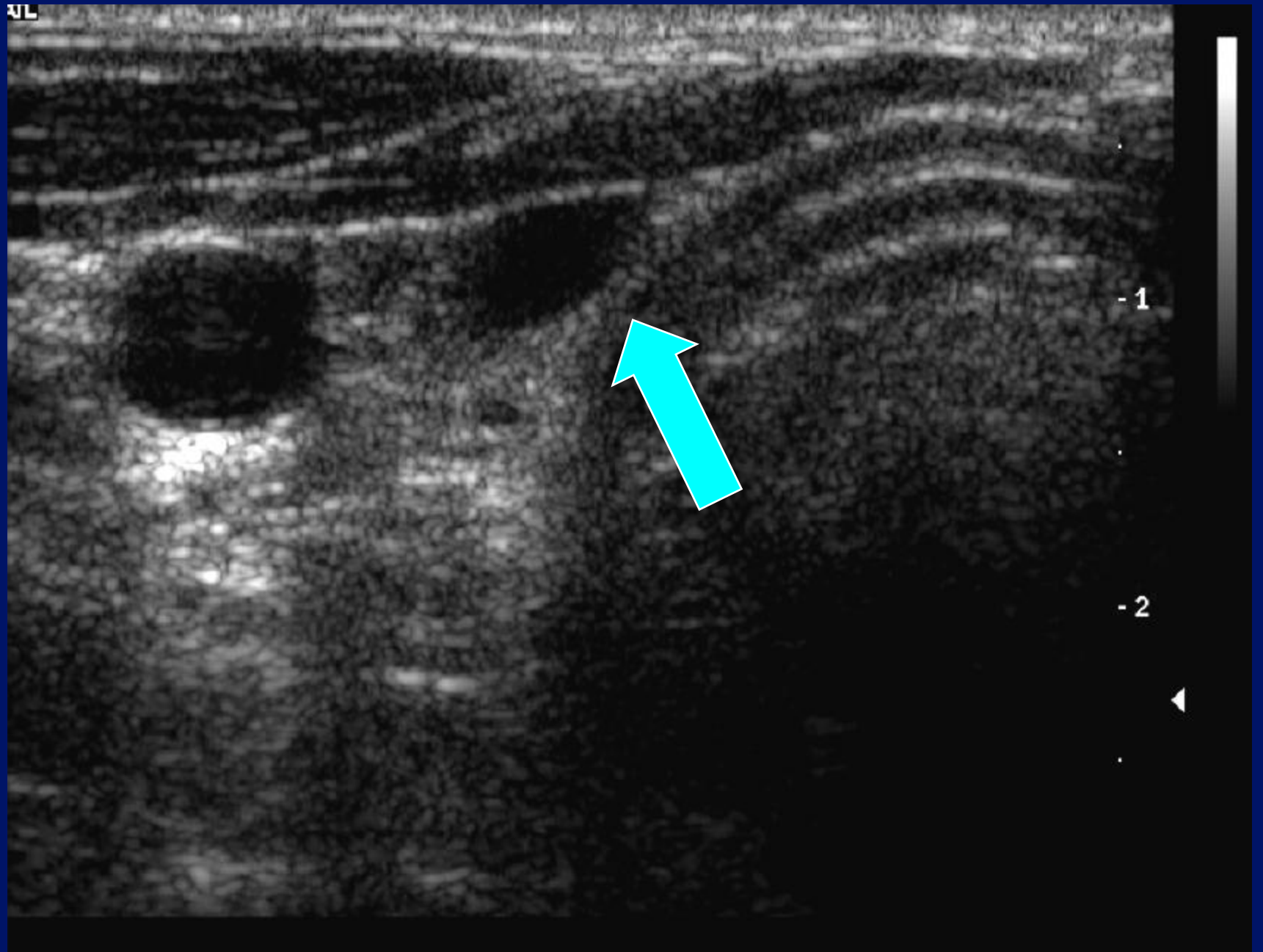
AL



AL

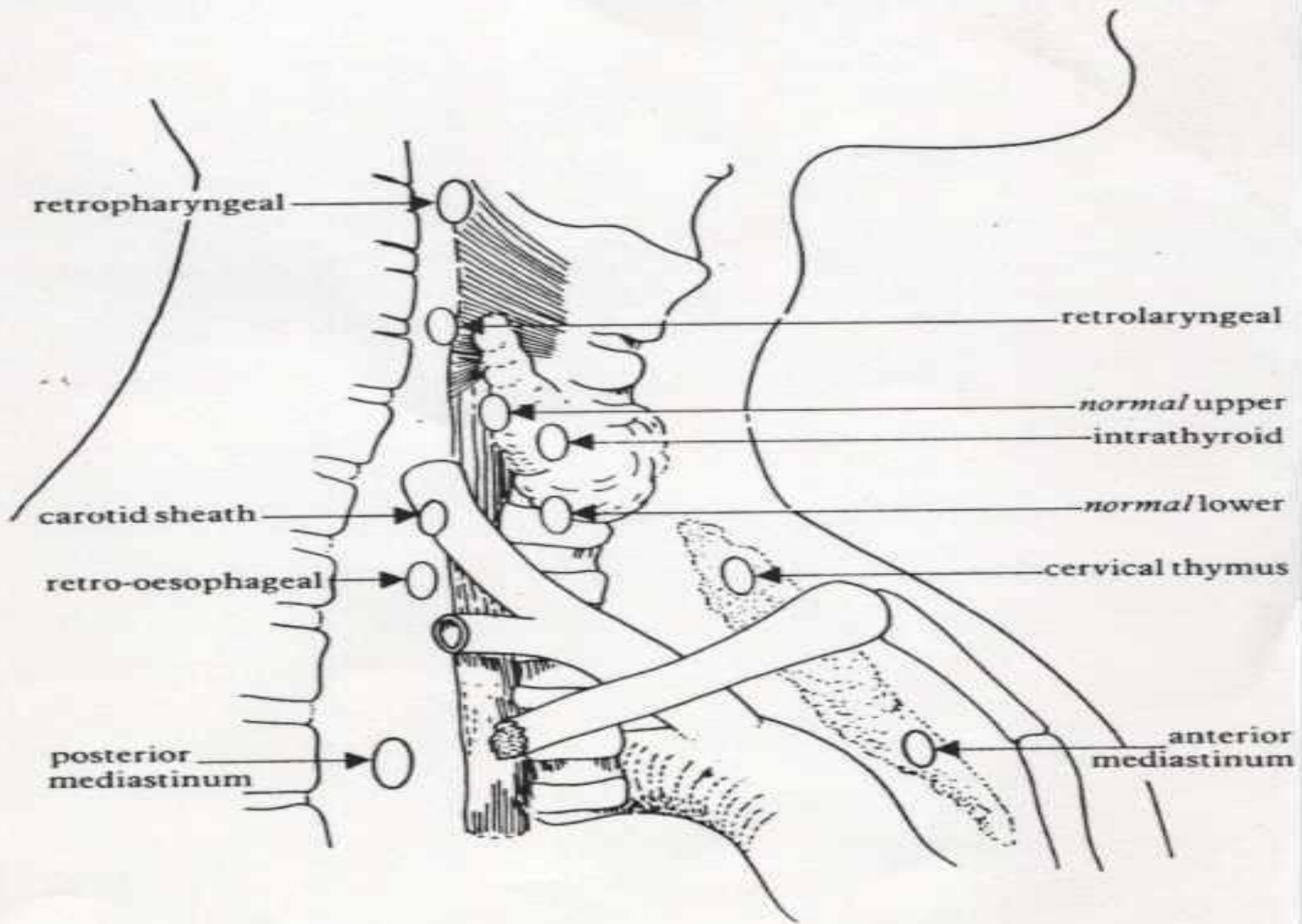


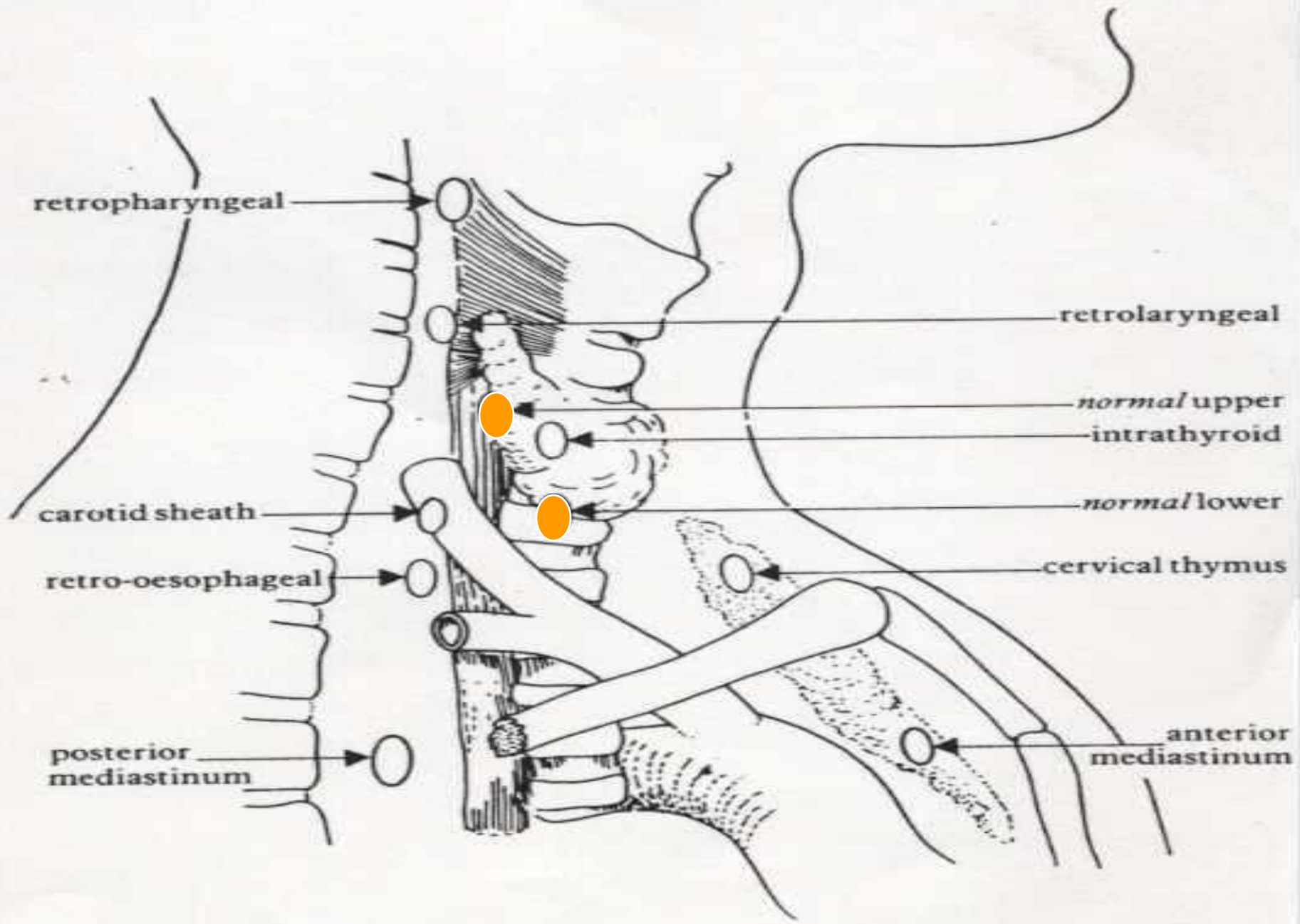
AL

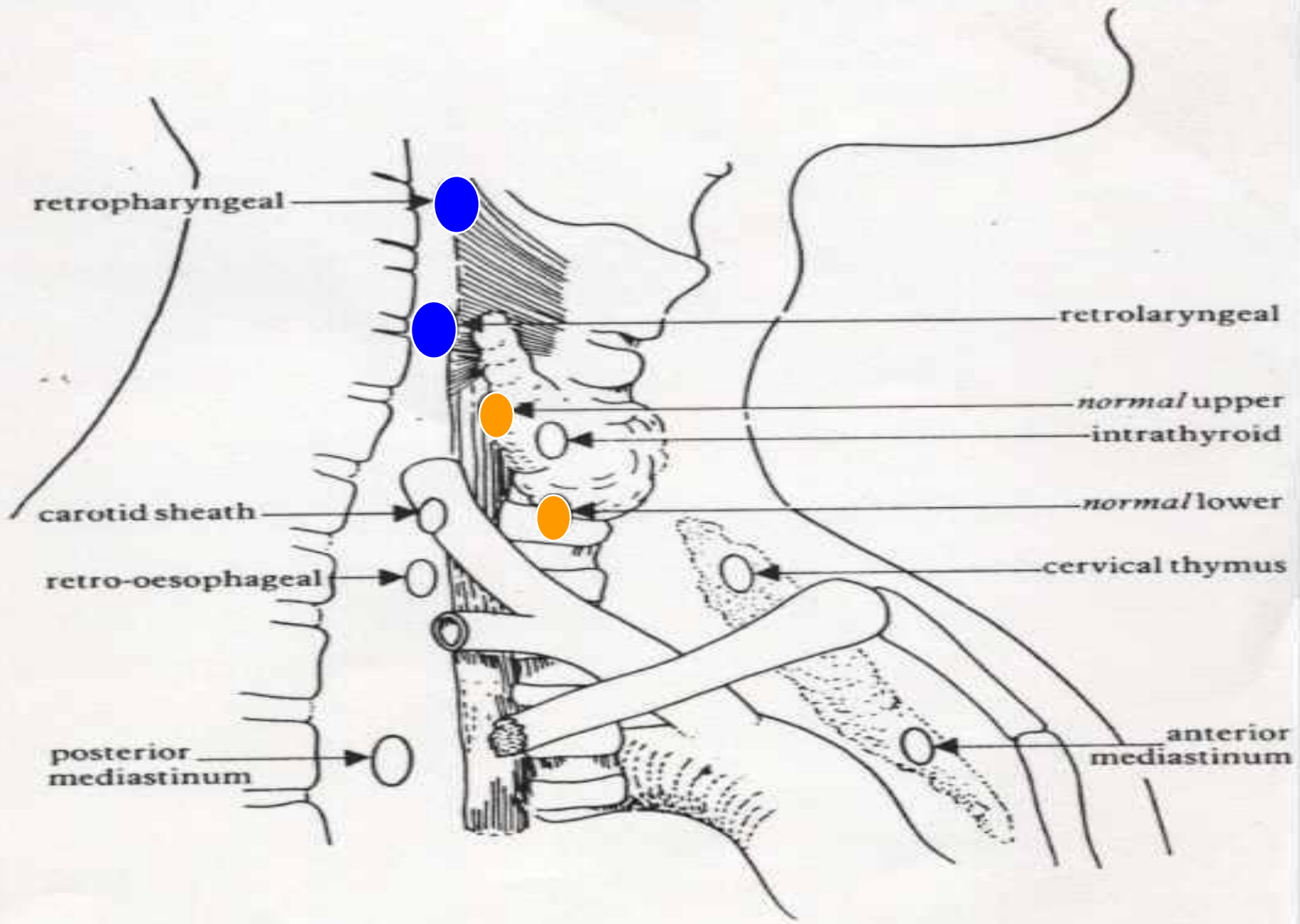


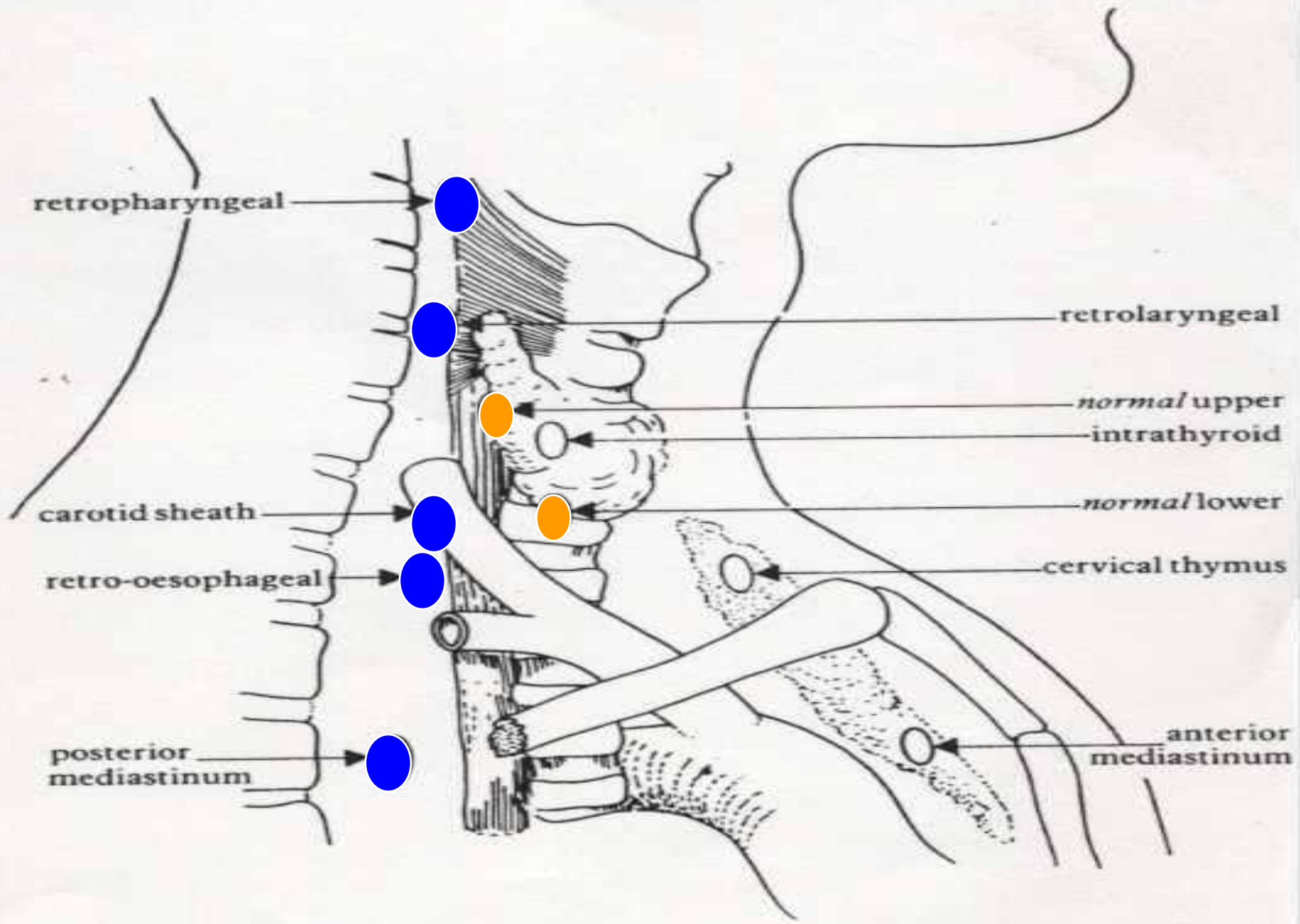
Localisation?

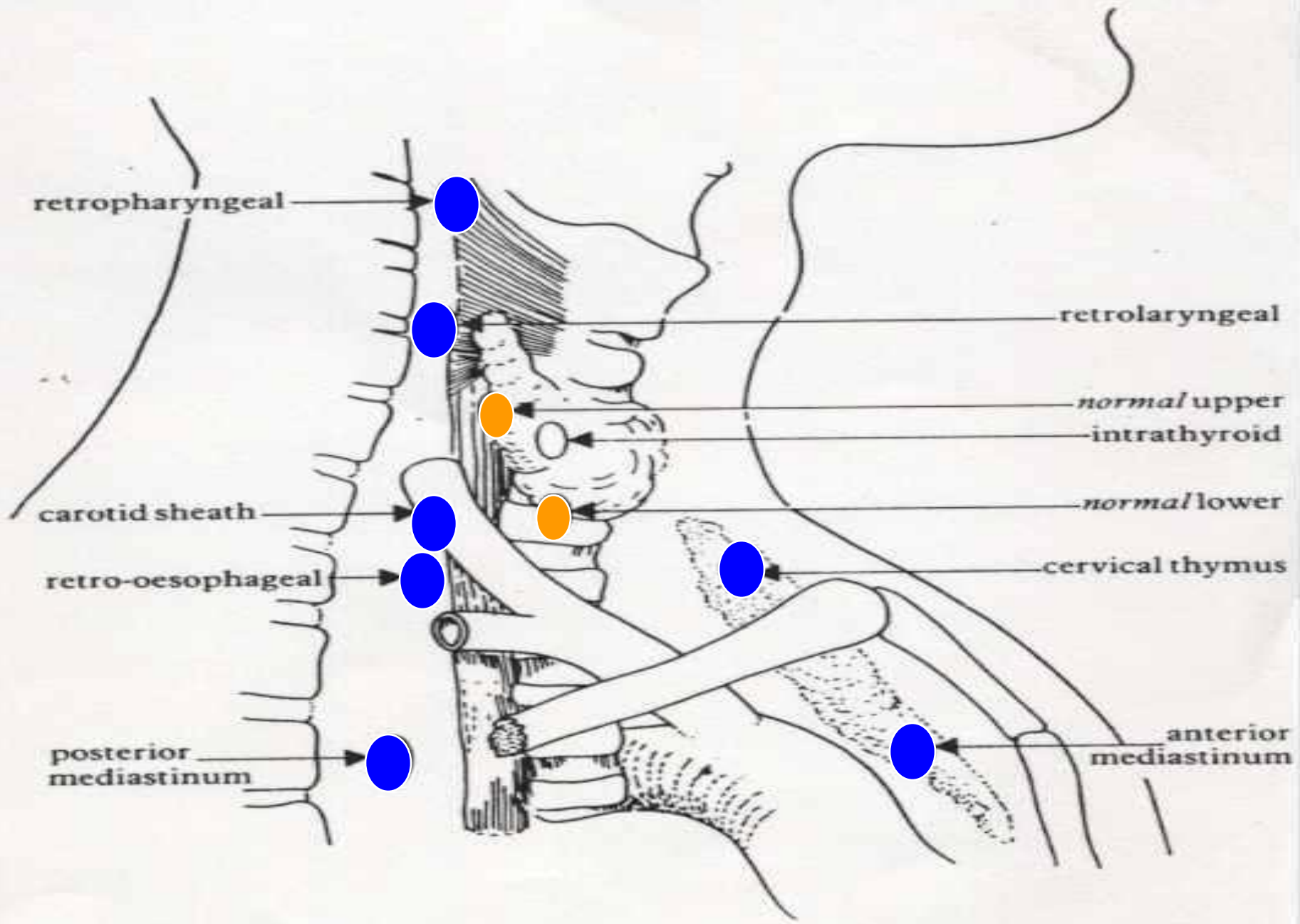
- Only 75% of abnormal parathyroids are found at the “normal” position.

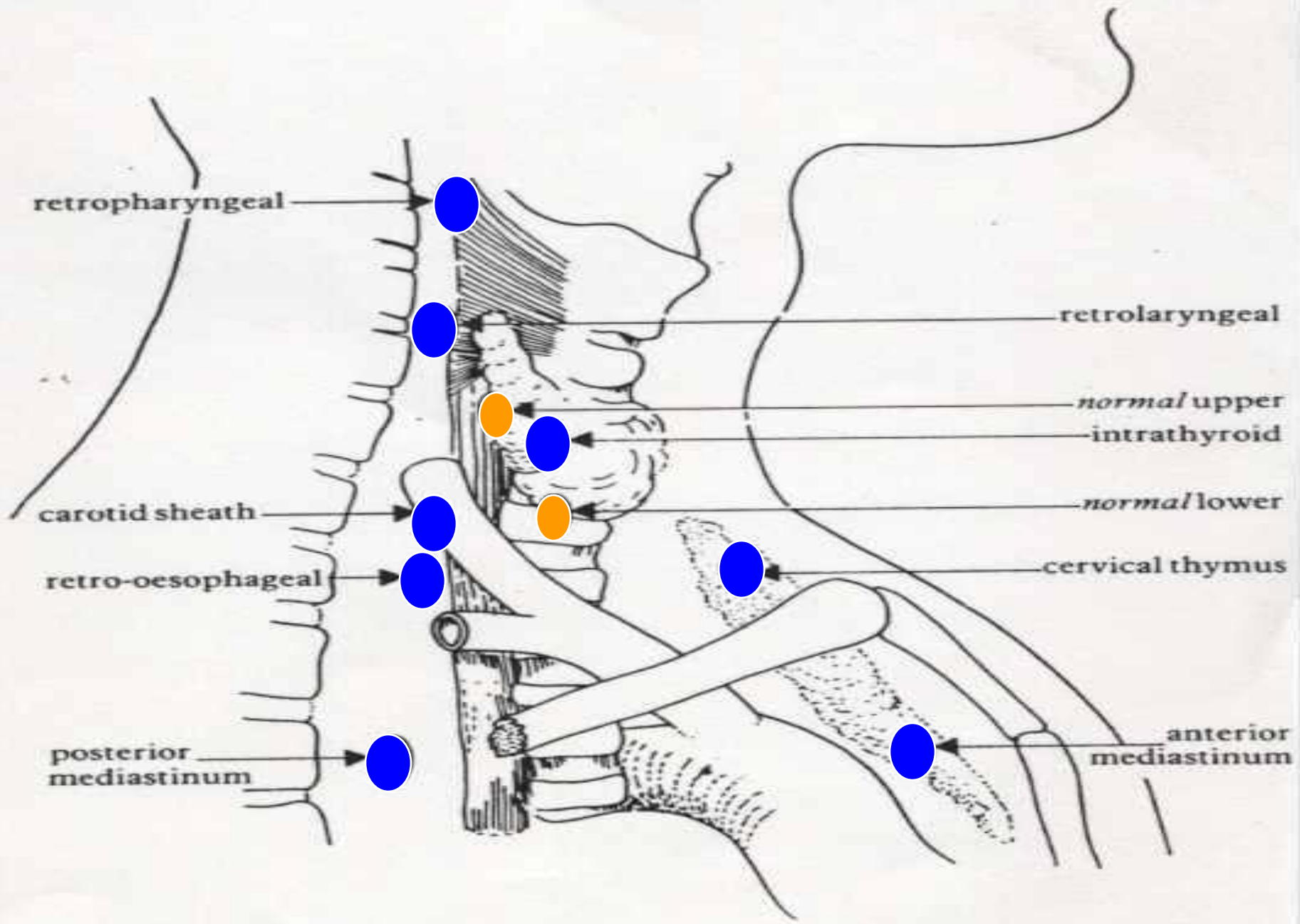










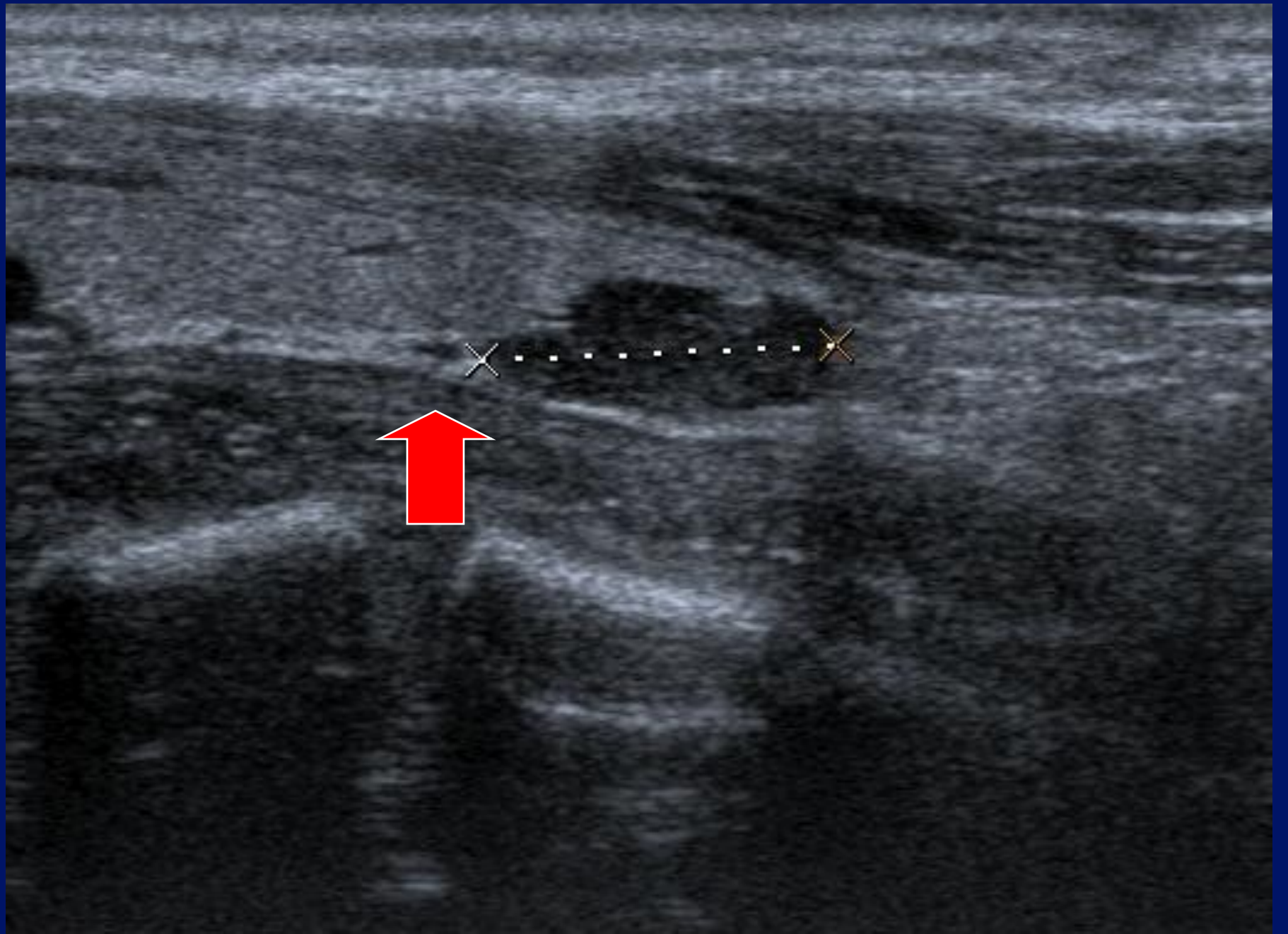


Intra-thyroid adenoma.

- 4%?
- Usually the inferior parathyroid.
- Sub-capsular.
- Intra-thyroid.



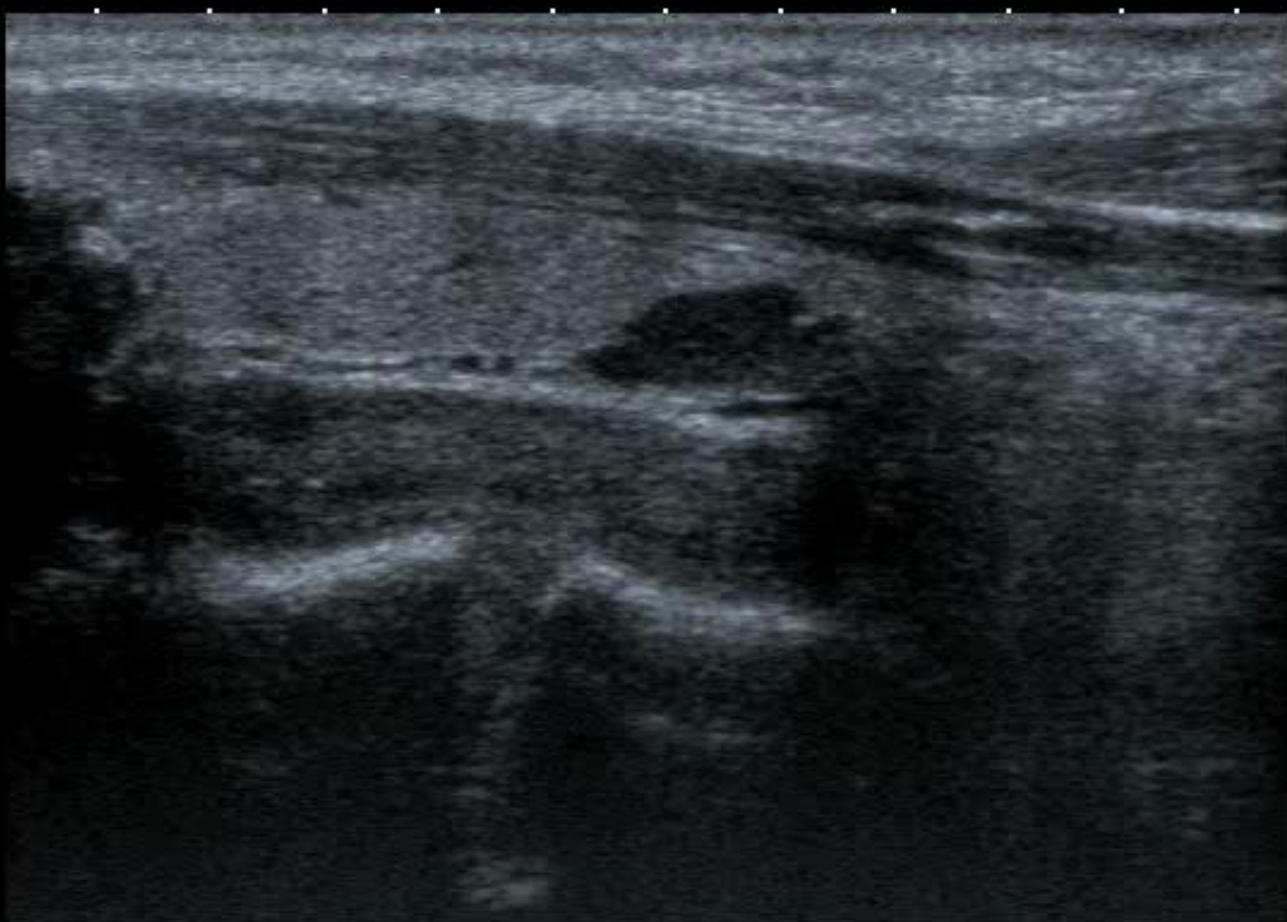




Left inferior parathyroidectomy.

“Despite pre operative localisation
and extensive search – no adenoma
found”

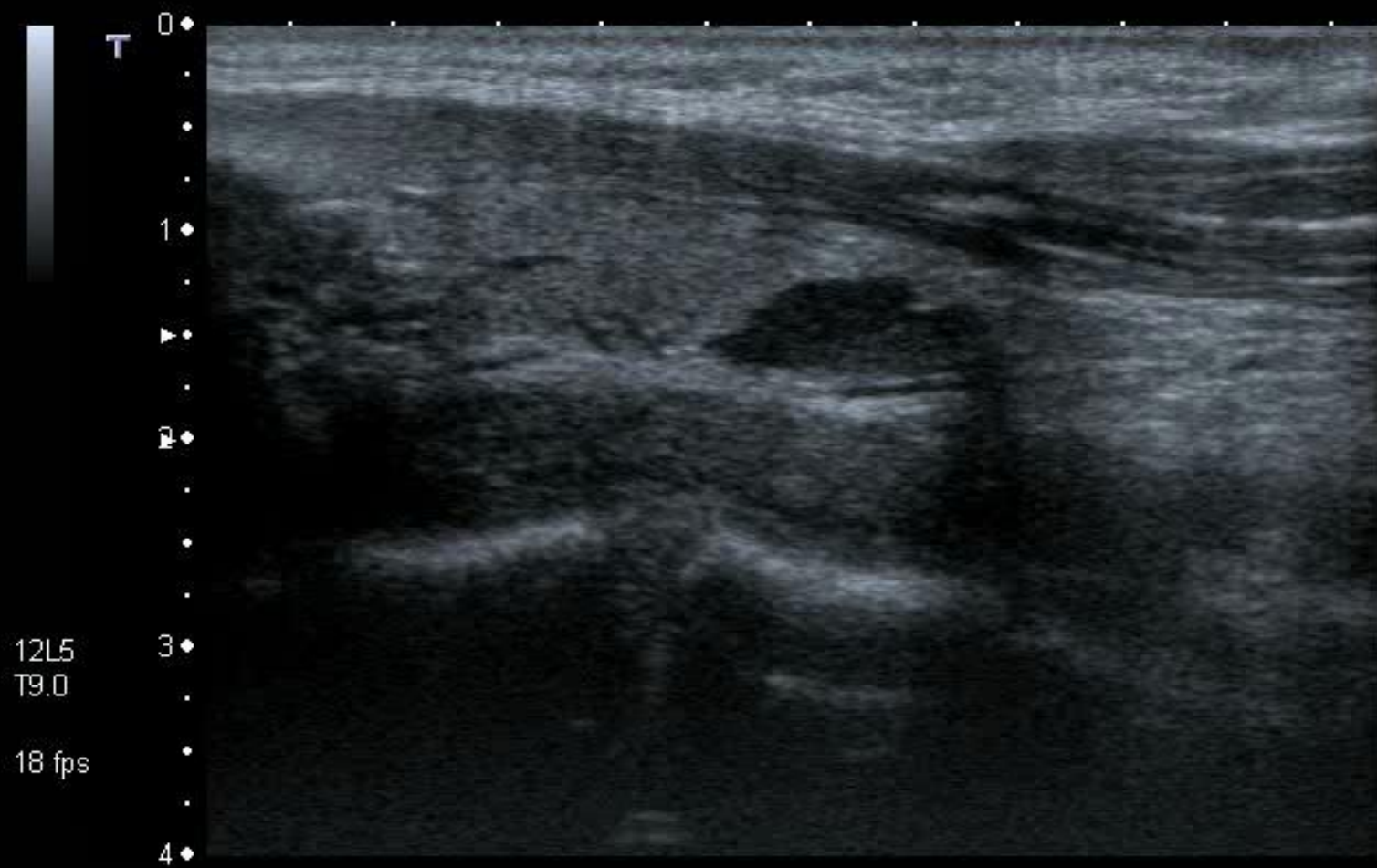T
0 ◆
.
.
1 ◆
.
▼
.
2 ◆
.
.
3 ◆
.
.
4 ◆



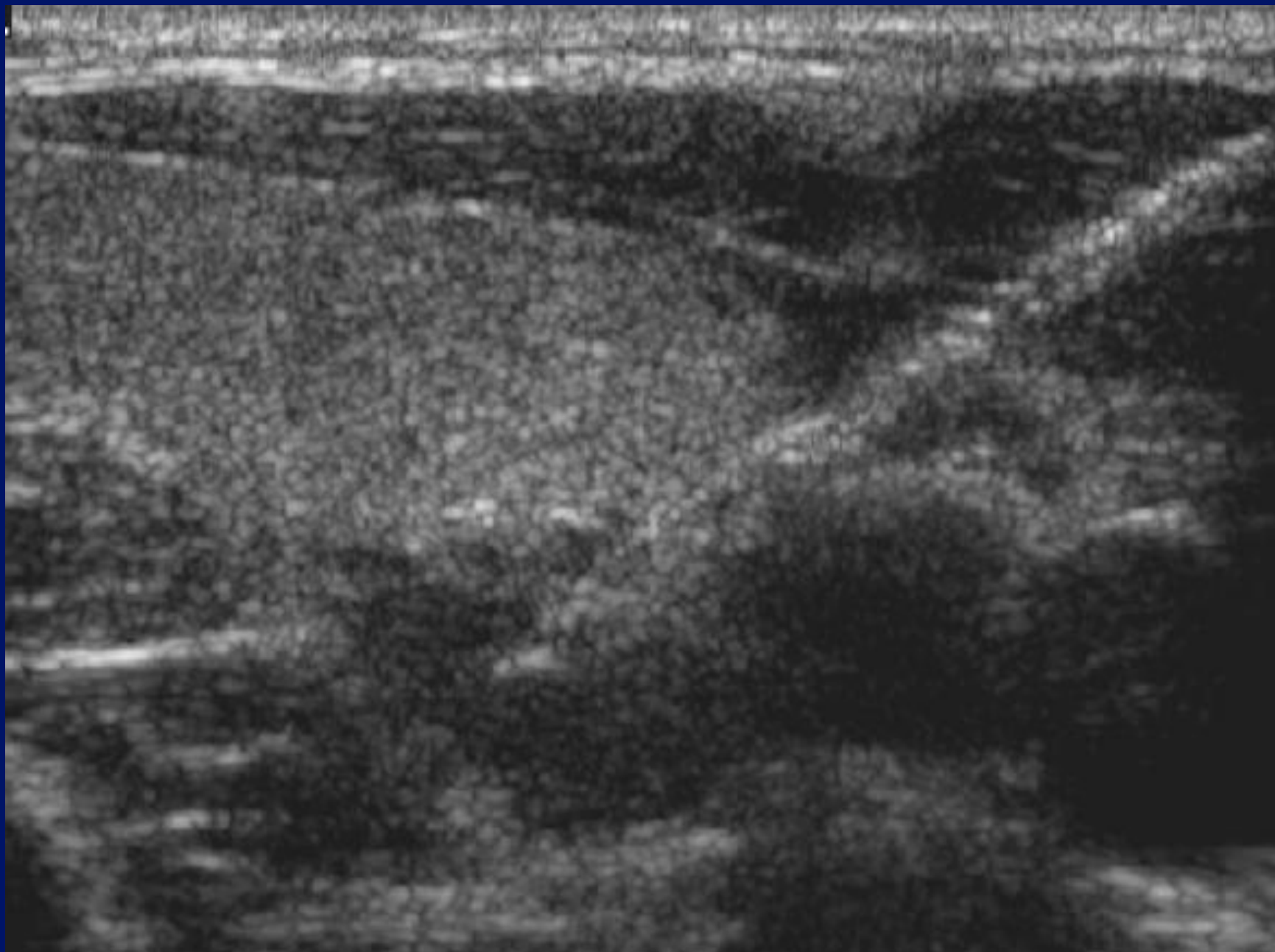
MI: 1.6
2DG
89
DR
70

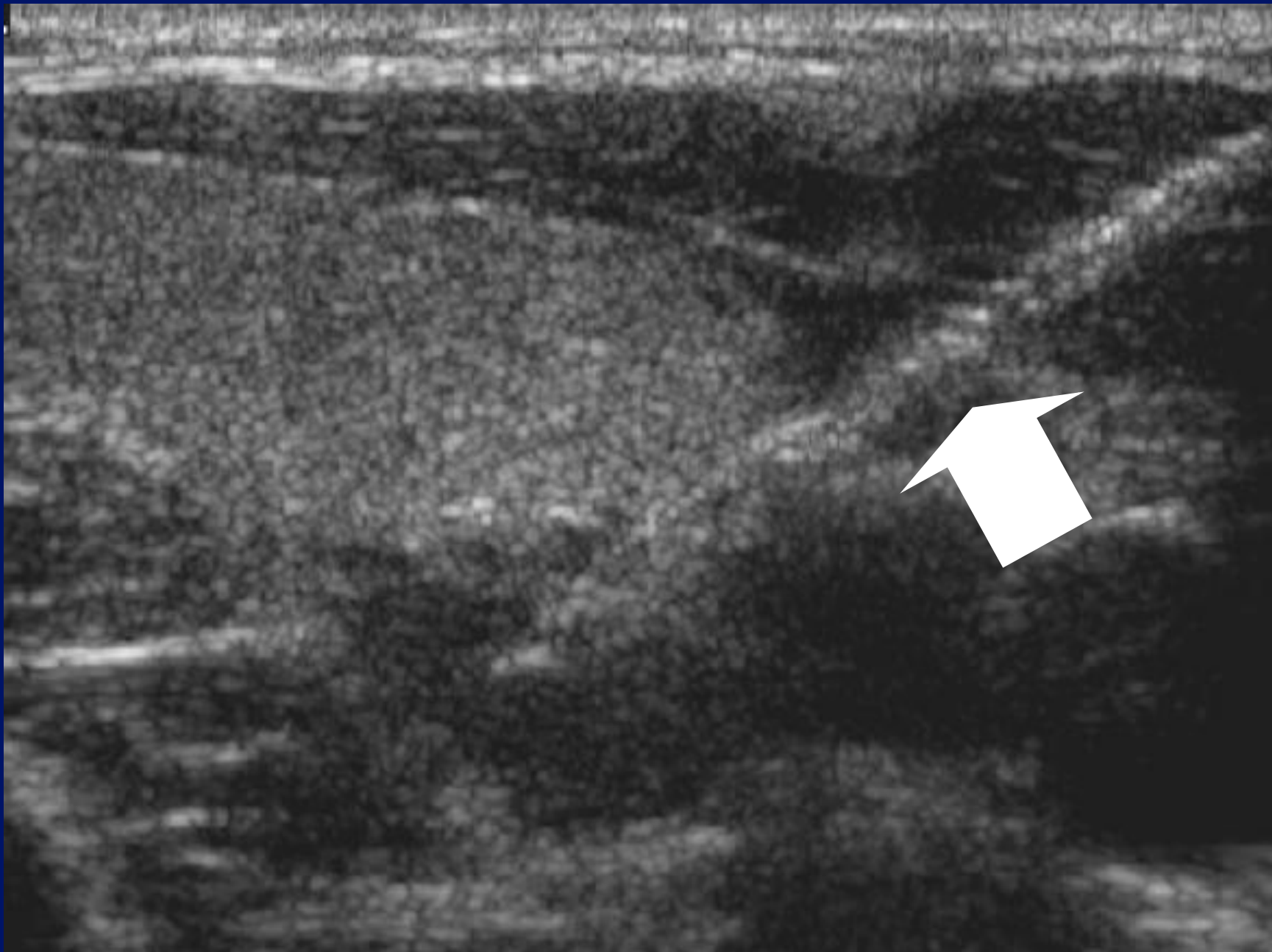
12L5
T9.0
18 fps





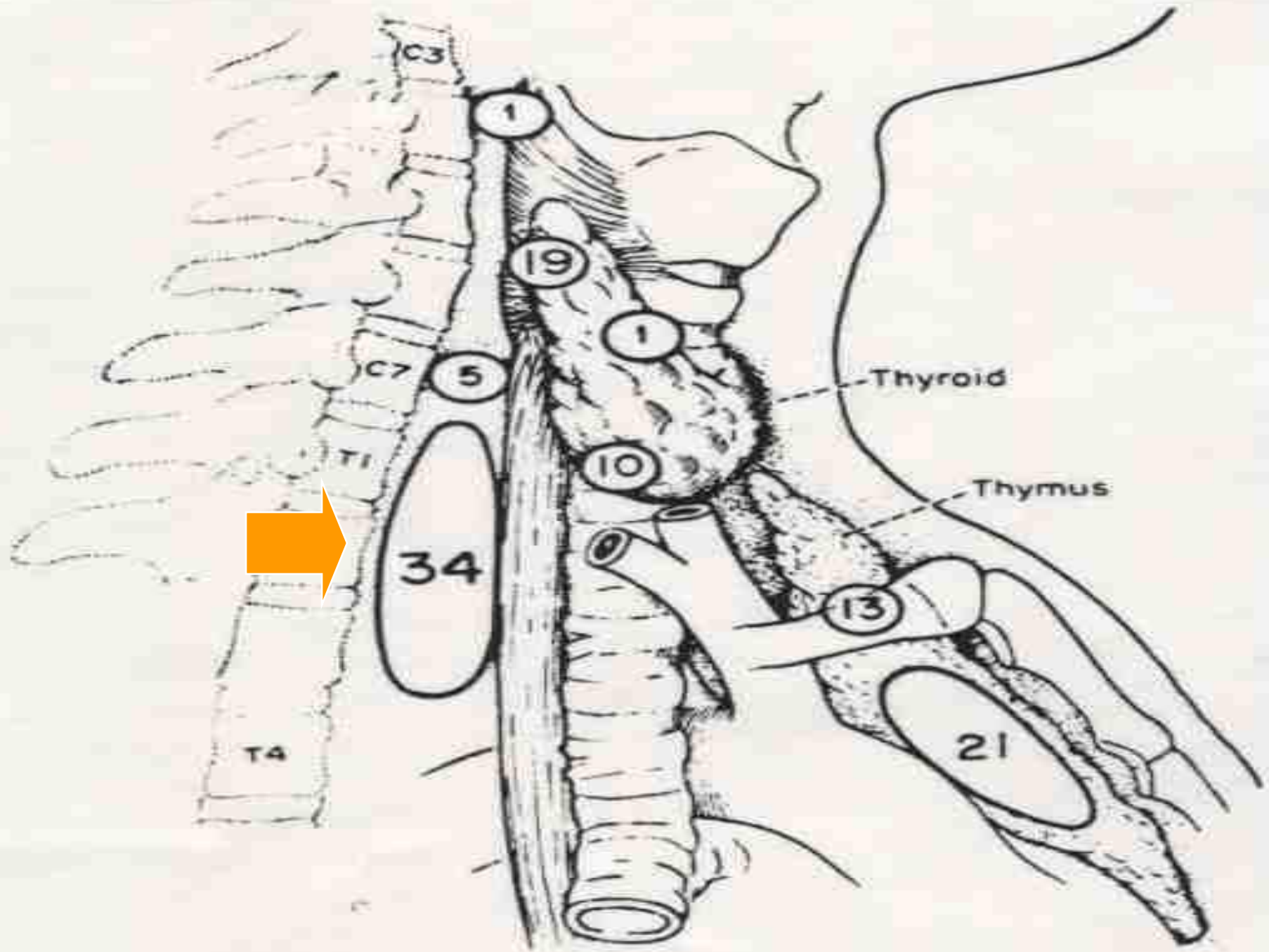
Archive job is not accepted. Please try again.





“Missed adenomas”

- 104 re-operations.
- Positions of adenomas found.
- All amenable to a neck incision.



34

5

19

1

10

13

21

C3

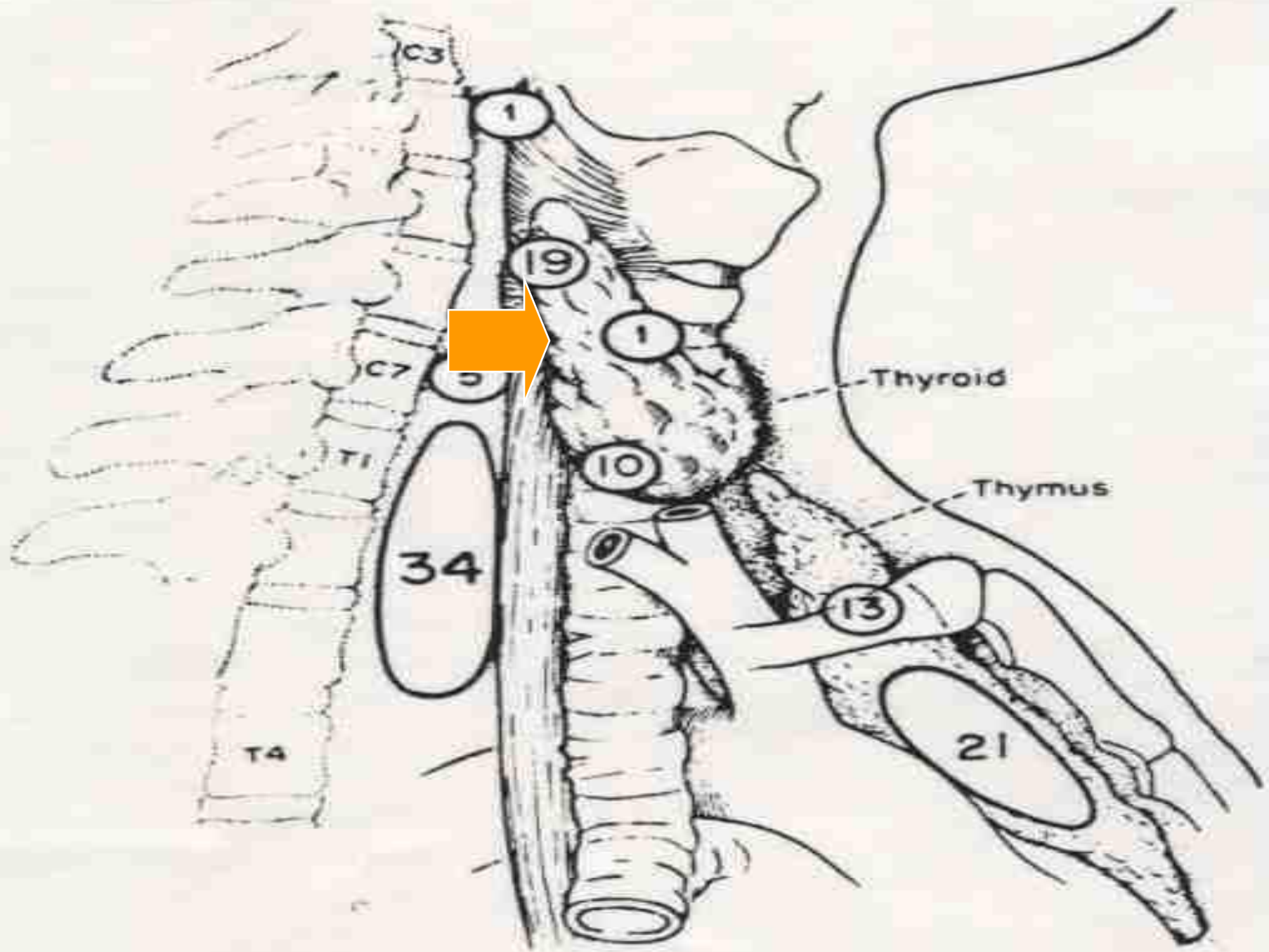
C7

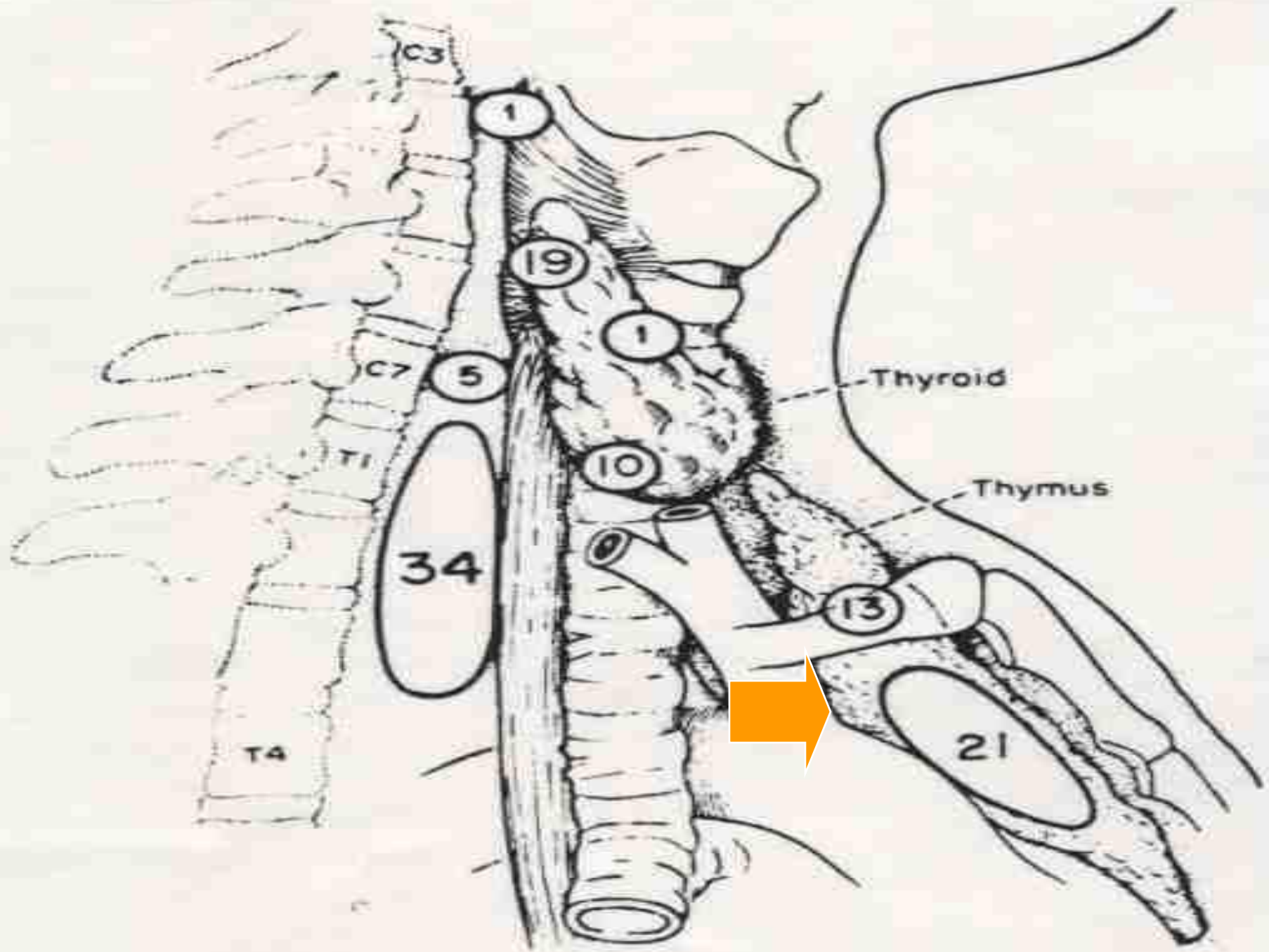
T1

T4

Thyroid

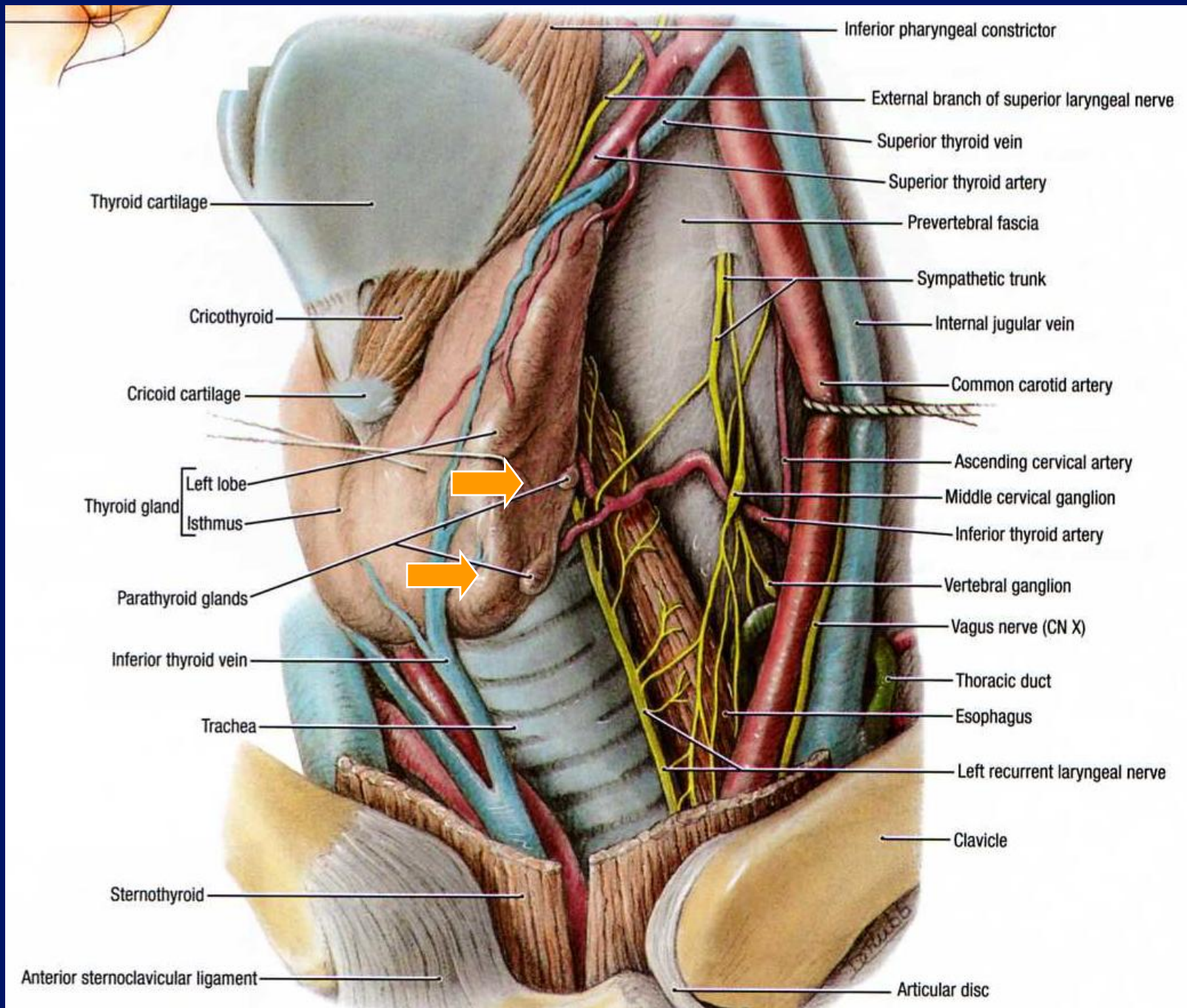
Thymus






Ultrasound Technique

- Transverse imaging .
- Retro – thyroid region.
- Neck extension.
- Infra – thyroid region.
- Para-tracheal region.
- Carotid sheath.
- Tracheo- oesophageal groove.




- Inferior pharyngeal constrictor
- External branch of superior laryngeal nerve
- Superior thyroid vein
- Superior thyroid artery
- Prevertebral fascia
- Sympathetic trunk
- Internal jugular vein
- Common carotid artery
- Ascending cervical artery
- Middle cervical ganglion
- Inferior thyroid artery
- Vertebral ganglion
- Vagus nerve (CN X)
- Thoracic duct
- Esophagus
- Left recurrent laryngeal nerve
- Clavicle
- Articular disc
- Thyroid cartilage
- Cricothyroid
- Cricoid cartilage
- Thyroid gland
 - Left lobe
 - Isthmus
- Parathyroid glands
- Inferior thyroid vein
- Trachea
- Sternothyroid
- Anterior sternoclavicular ligament

Superior.





Extra-thyroid?





Differential diagnosis : thyroid nodules.

Inferior.



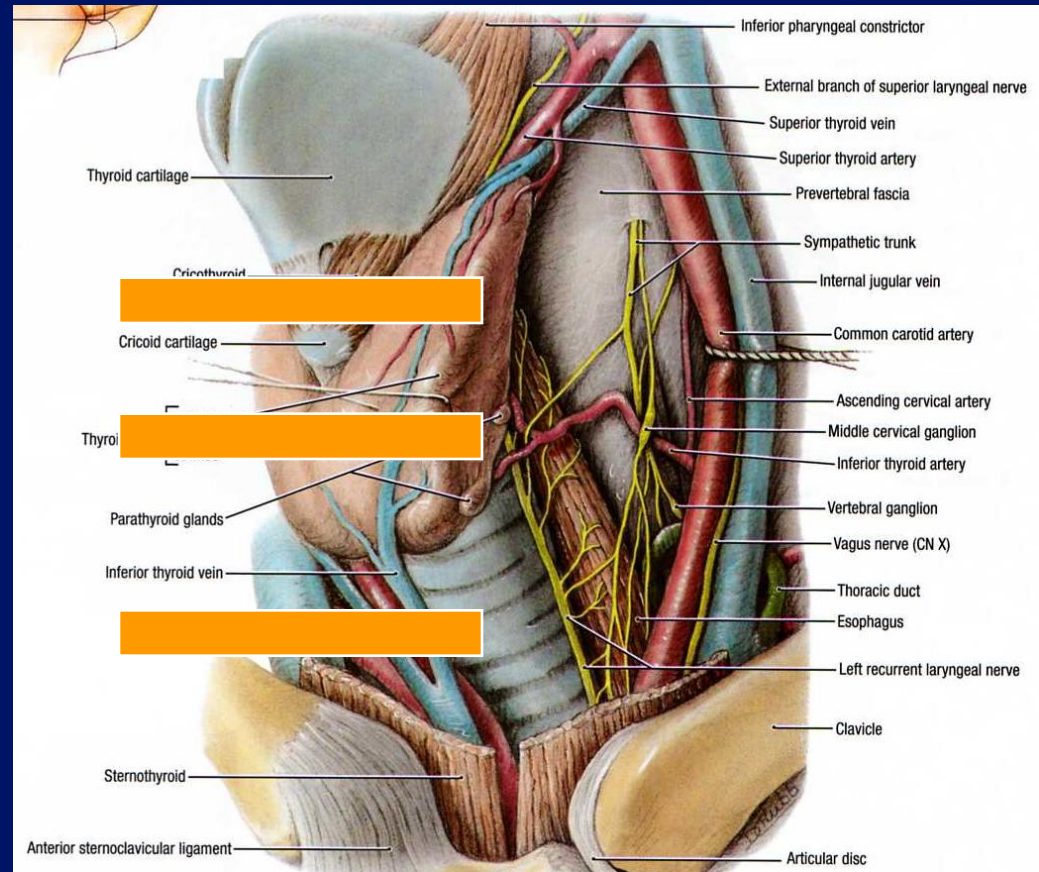


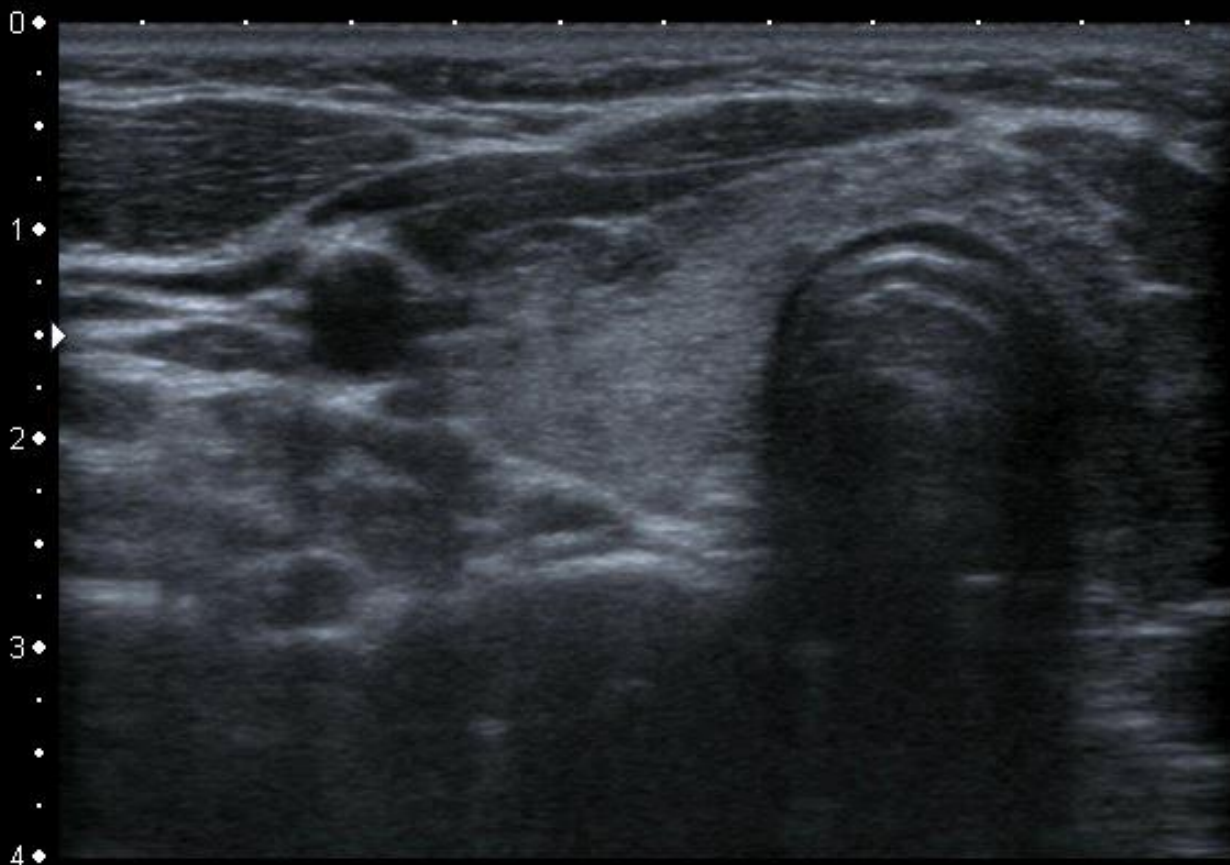
Differential diagnosis : lymph nodes.



Differential diagnosis : lymph nodes.

Ultrasound Technique





T

MI:1.6
2DG
80
DR
65


12L5
diffT8.0

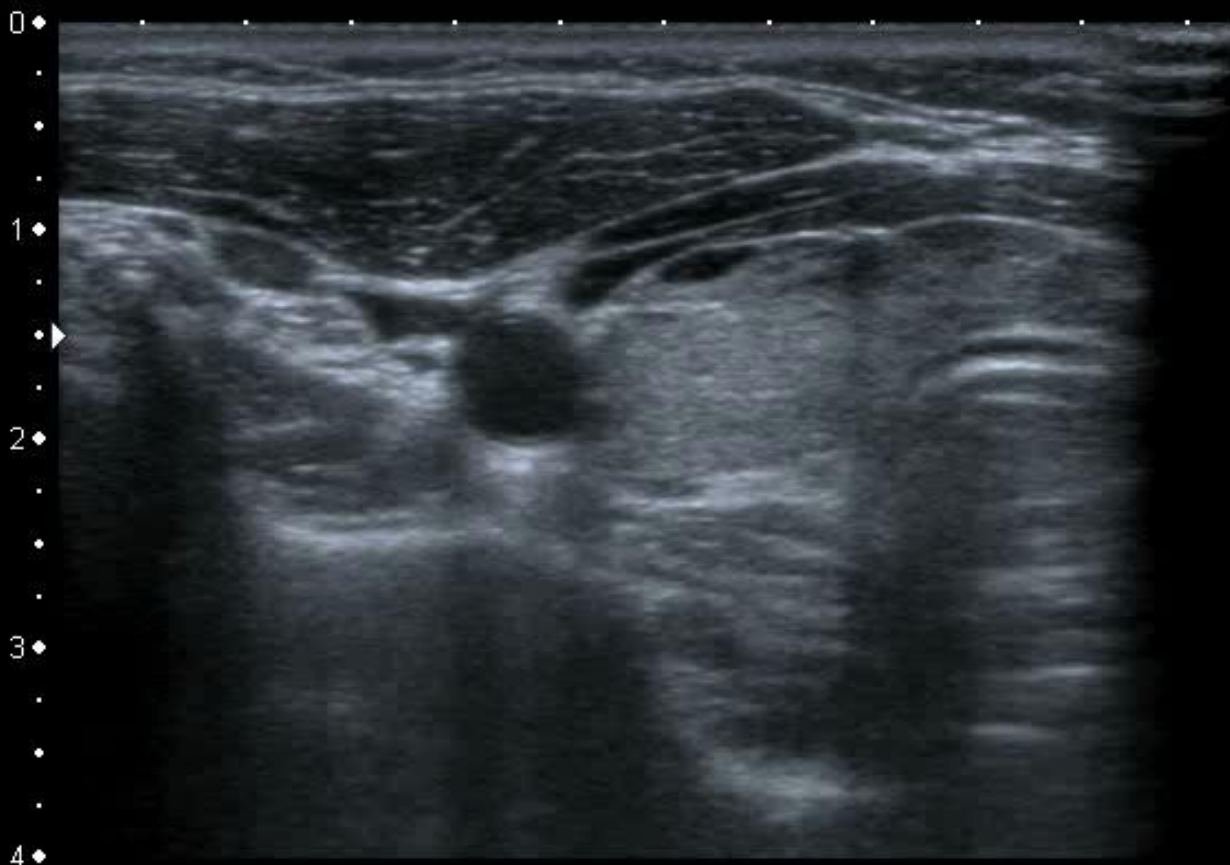
36 fps

0
1
2
3
4

A.0 IP6

HDD:94% Free





T

MI:1.6
2DG
80
DR
65


12L5
diffT8.0

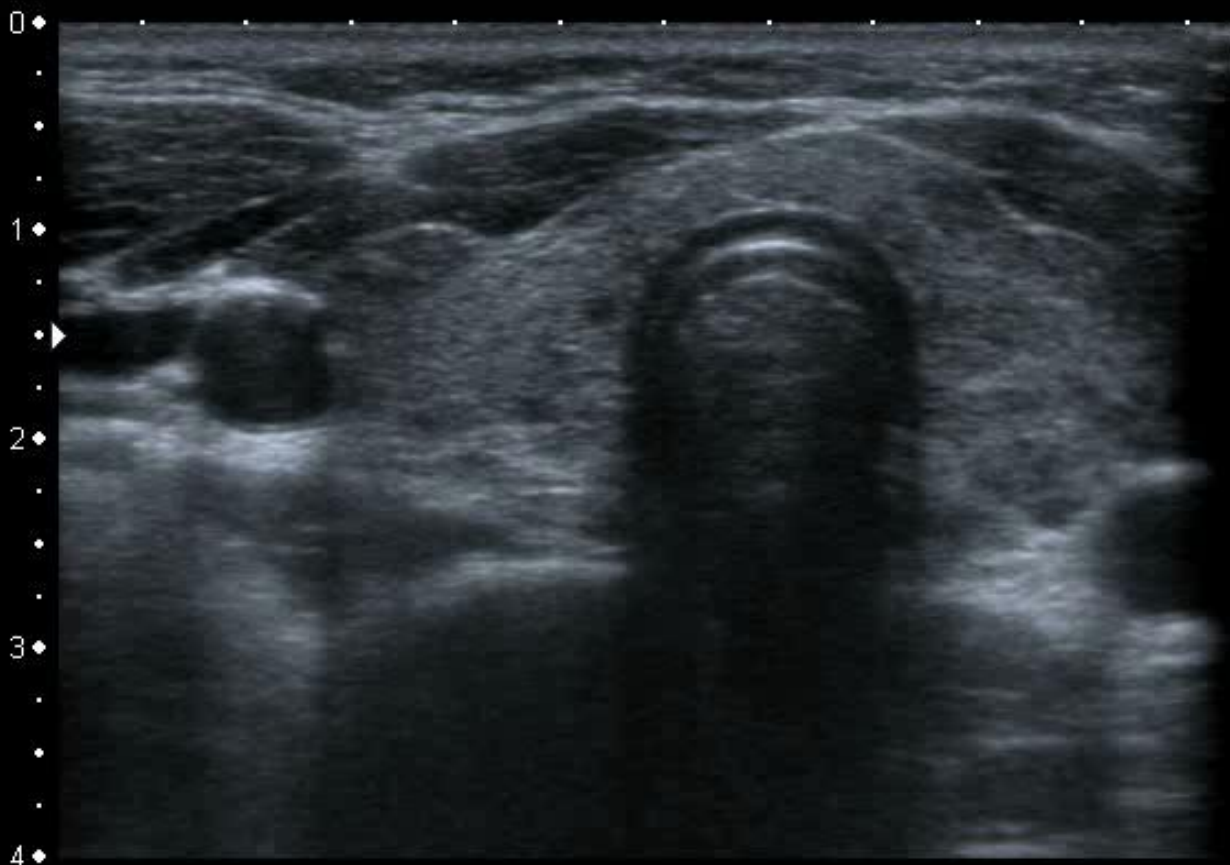
36 fps

0
1
2
3
4

A.0 IP6

HDD:94% Free






T

MI: 1.6
2DG
80
DR
65

12L5
diffT8.0
36 fps

A.0 IP6

HDD: 94% Free



T

0 ◆

1 ◆▶


2 ◆

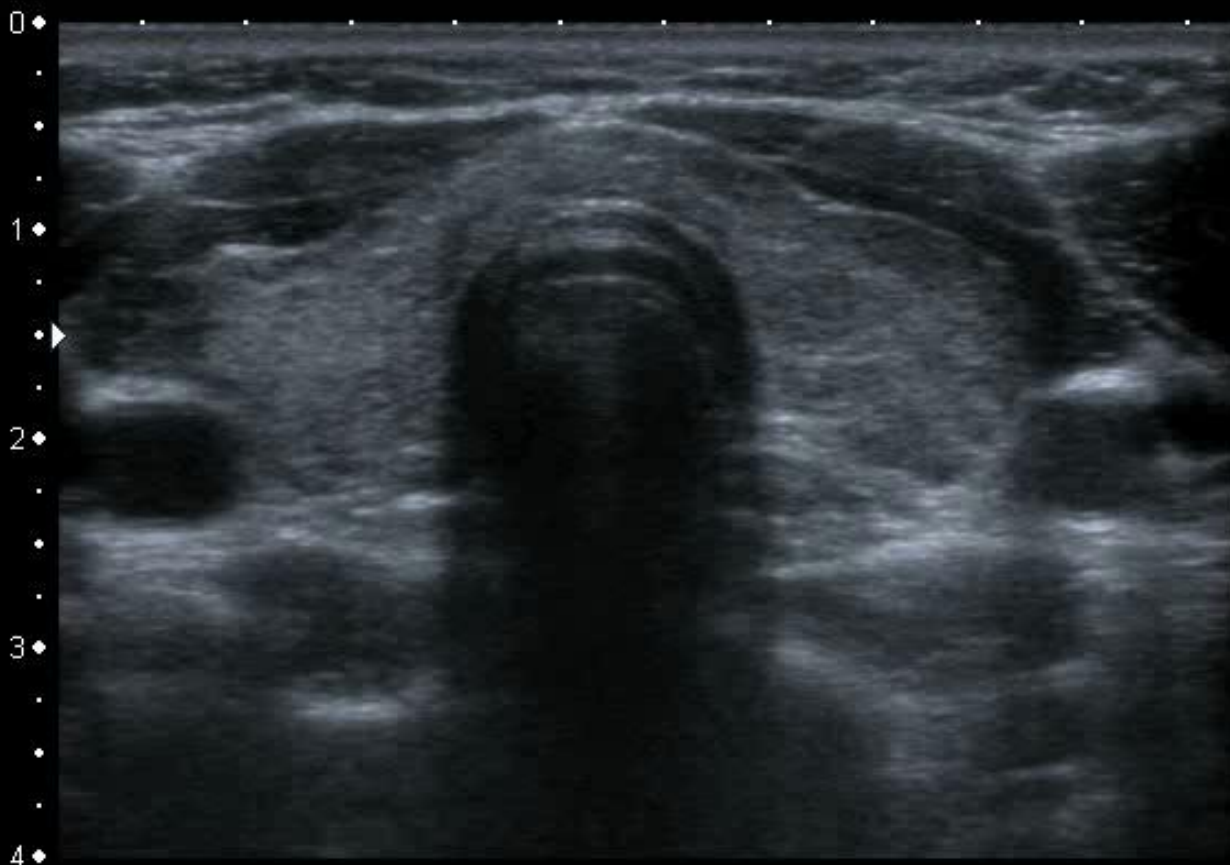
MI: 1.6
2DG
80
DR
65

12L5
diffT8.0
36 fps

A.0 IP6

HDD:94% Free





T

MI:1.6
2DG
80
DR
65

12L5
diffT8.0

36 fps

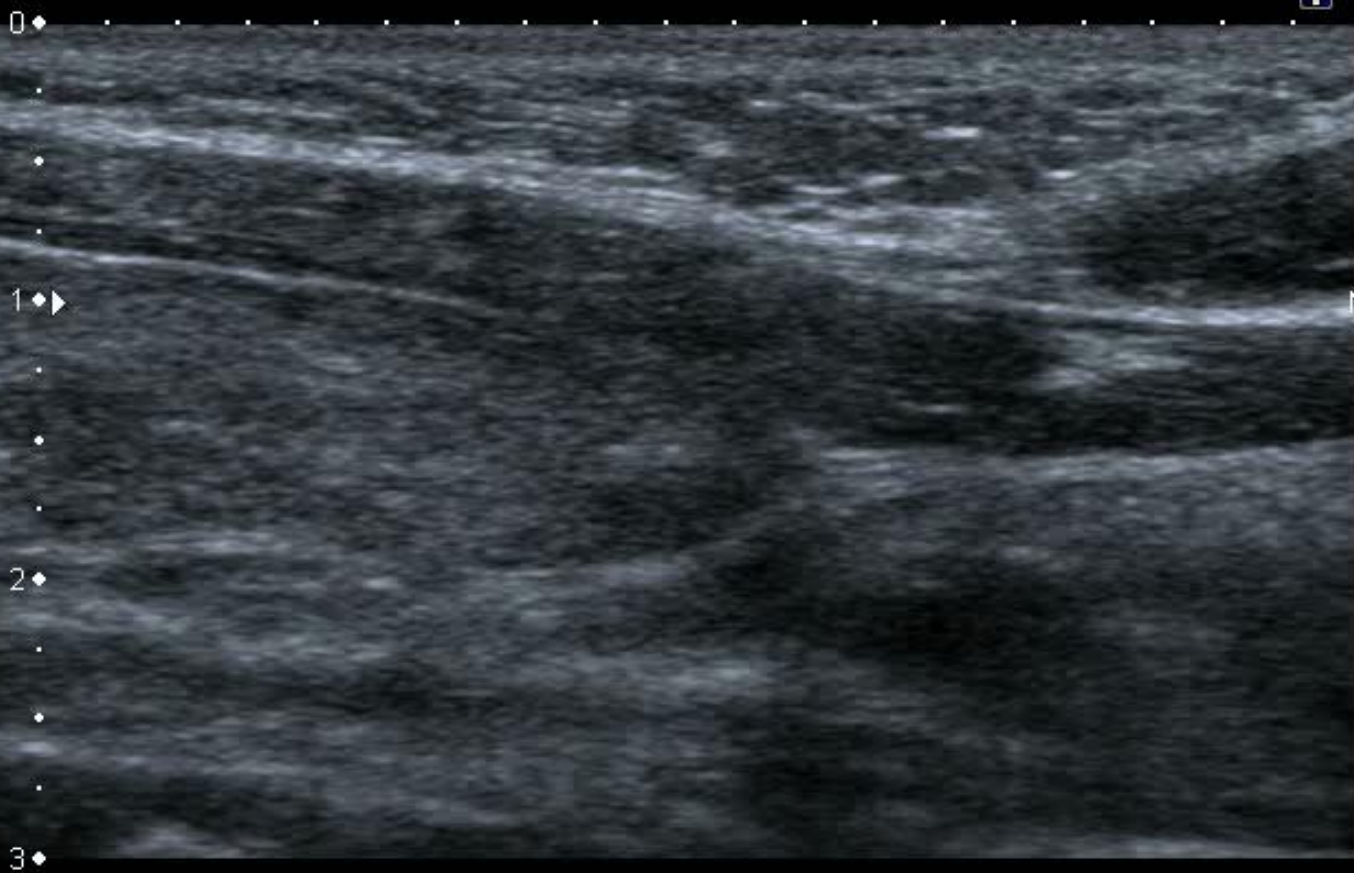0
1
2
3
4

A.0 IP6

HDD:94% Free



T



MI: 1.6
2DG
80
DR
65

12L5
diffT8.0
36 fps

A.0 IP6

HDD:94% Free



T

0

1

2

3


MI:1.6
2DG
80
DR
65

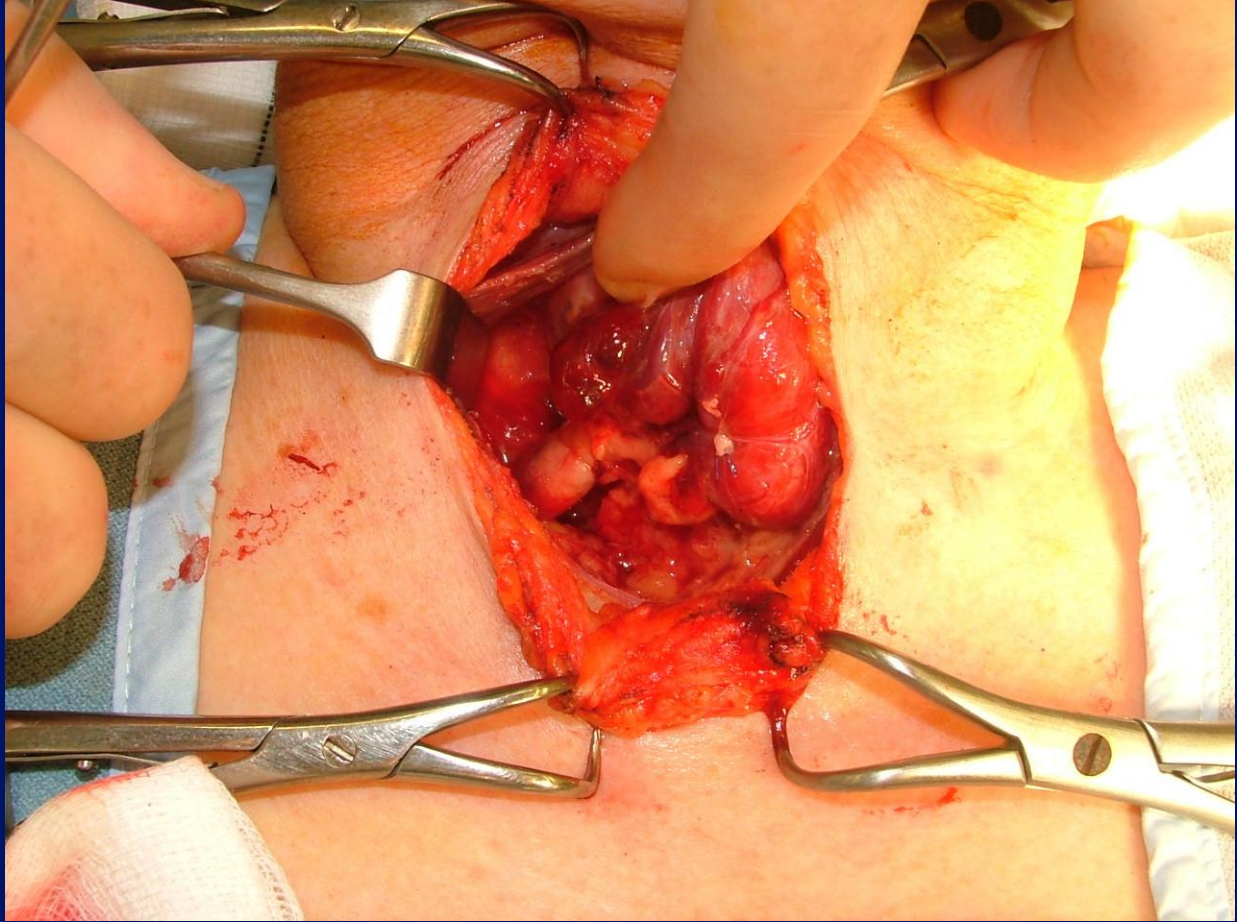
12L5
diffT8.0

36 fps

A 0 IP6

HDD:94% Free

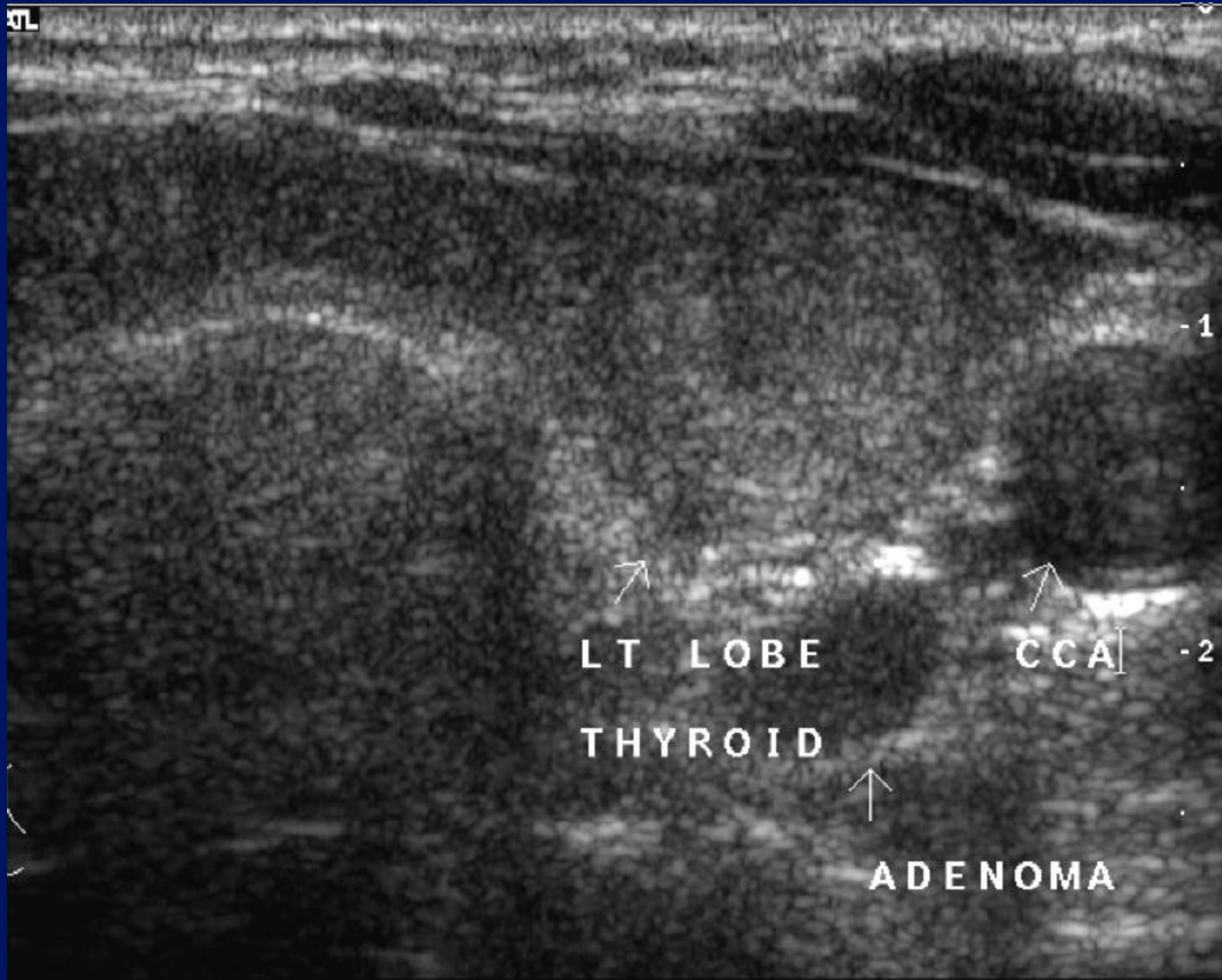




Our Practice?

- Surgery.
- Ultrasound first.
- Ultrasound negative – Sestamibi scanning.
- Sestamibi positive – occ. CT.(SPECT- CT)
- US & Sestamibi negative – failure of localisation.

57



ATL

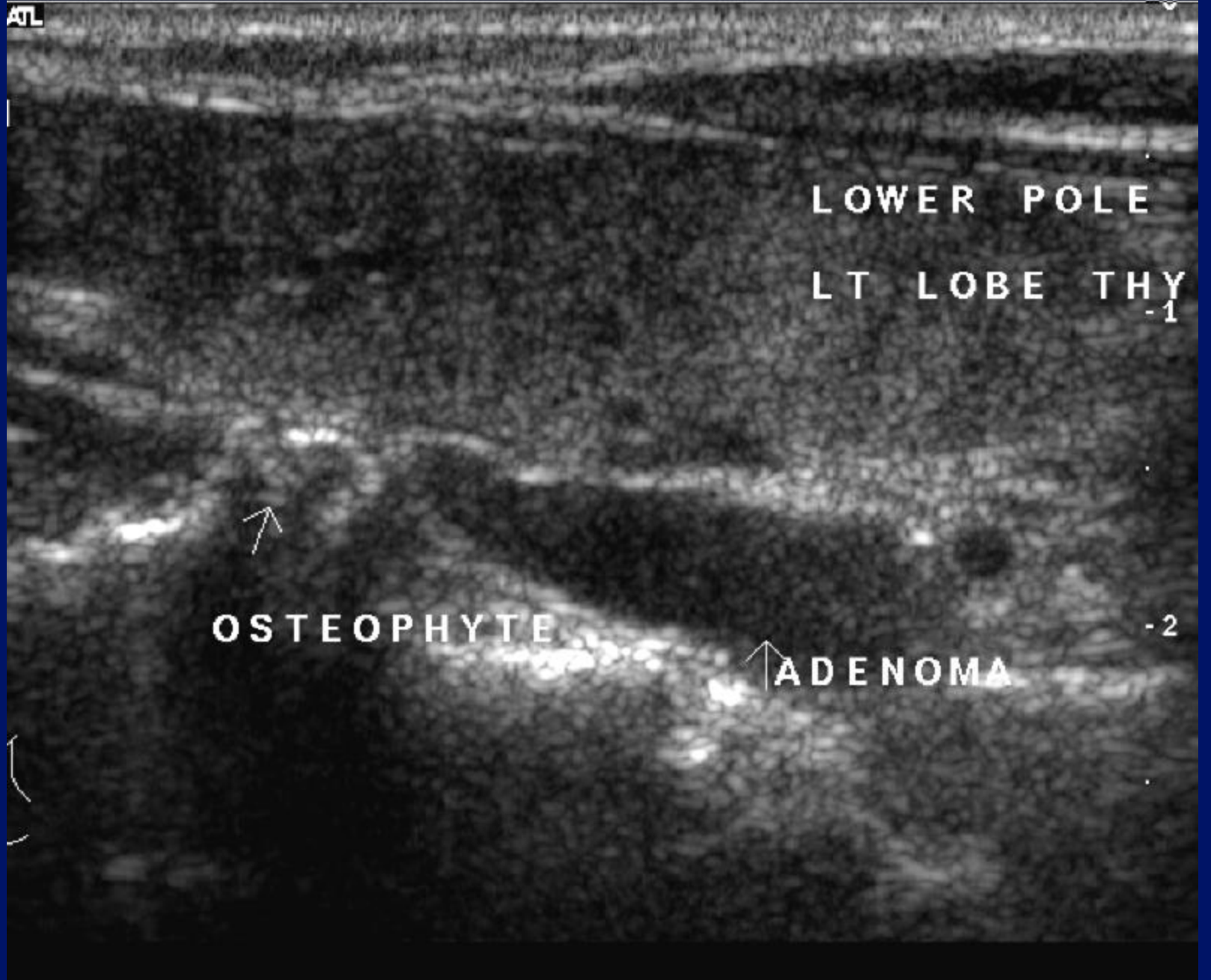
LOWER POLE

LT LOBE THY
-1

↑
OSTEOPHYTE

↑
ADENOMA

-2



ATL

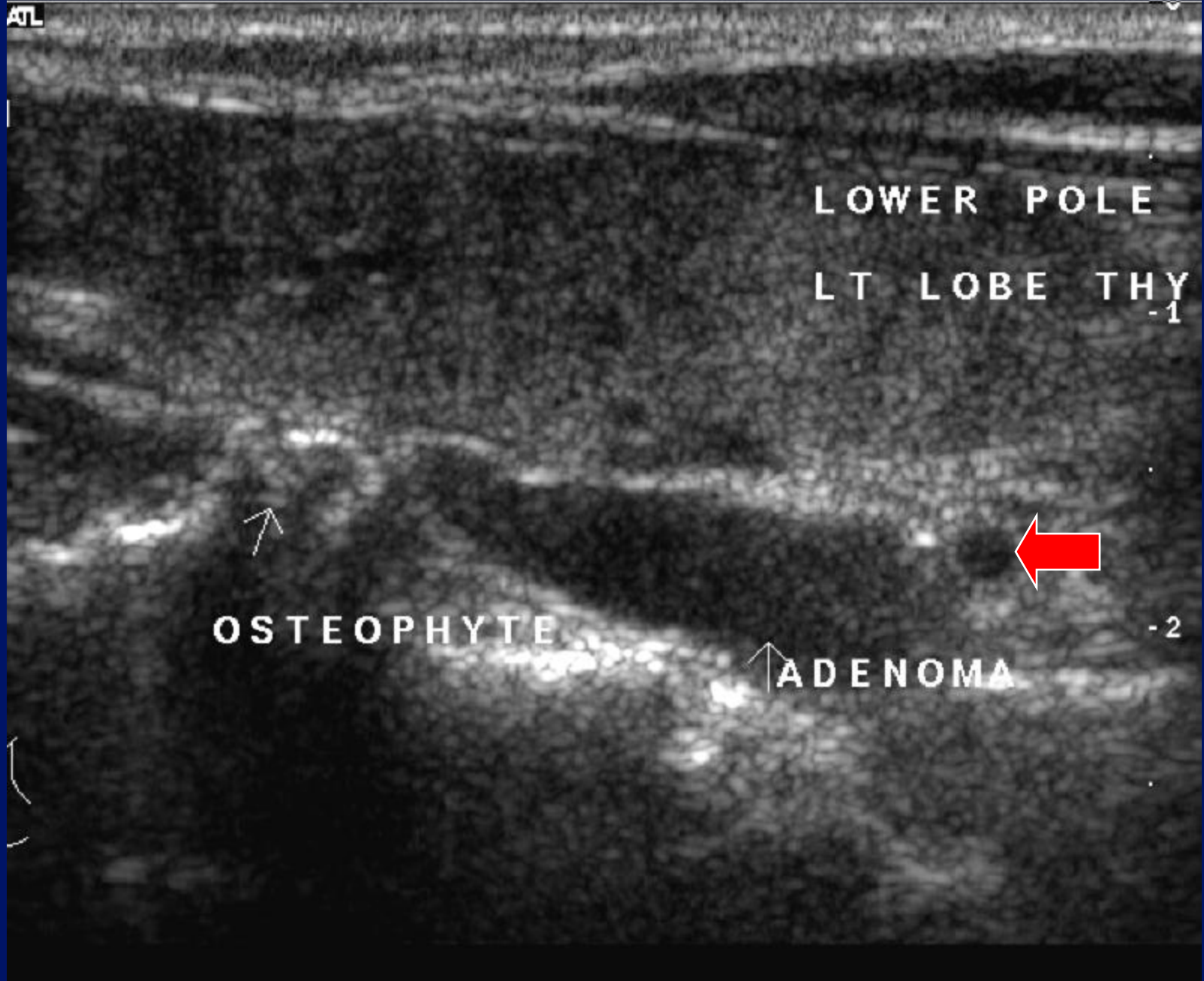
LOWER POLE

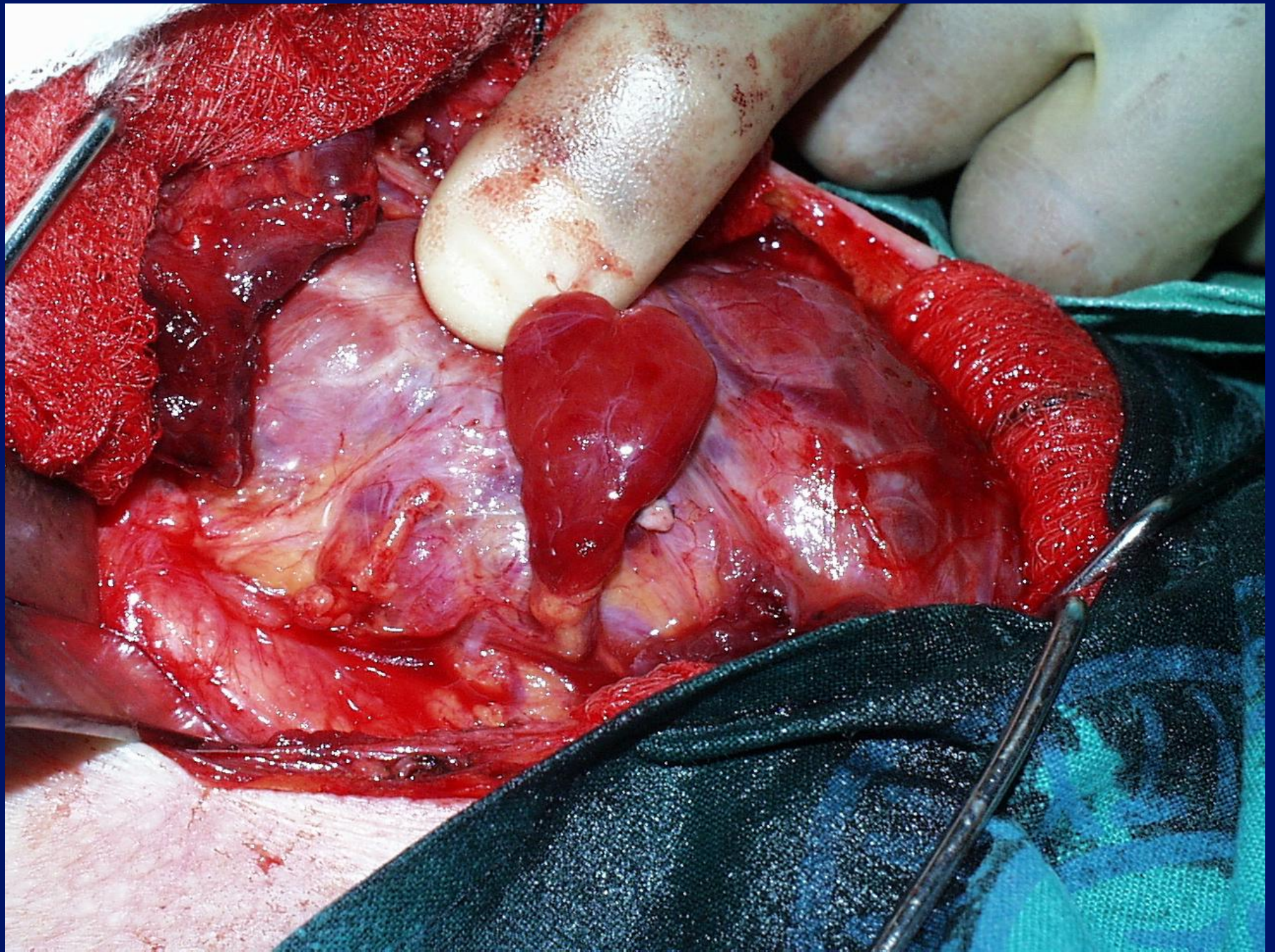
LT LOBE THY
-1

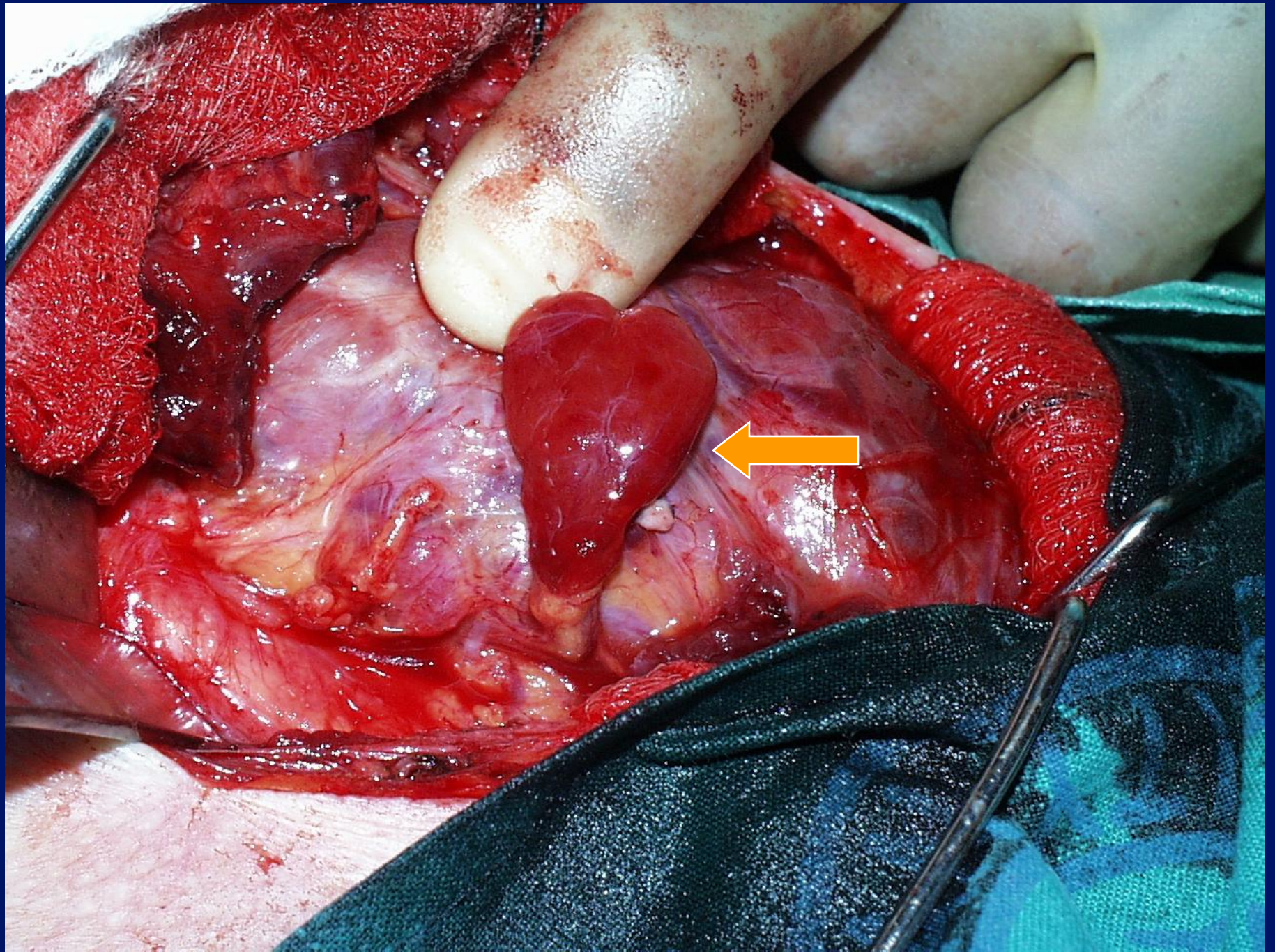
↑
OSTEOPHYTE

↑
ADENOMA

-2





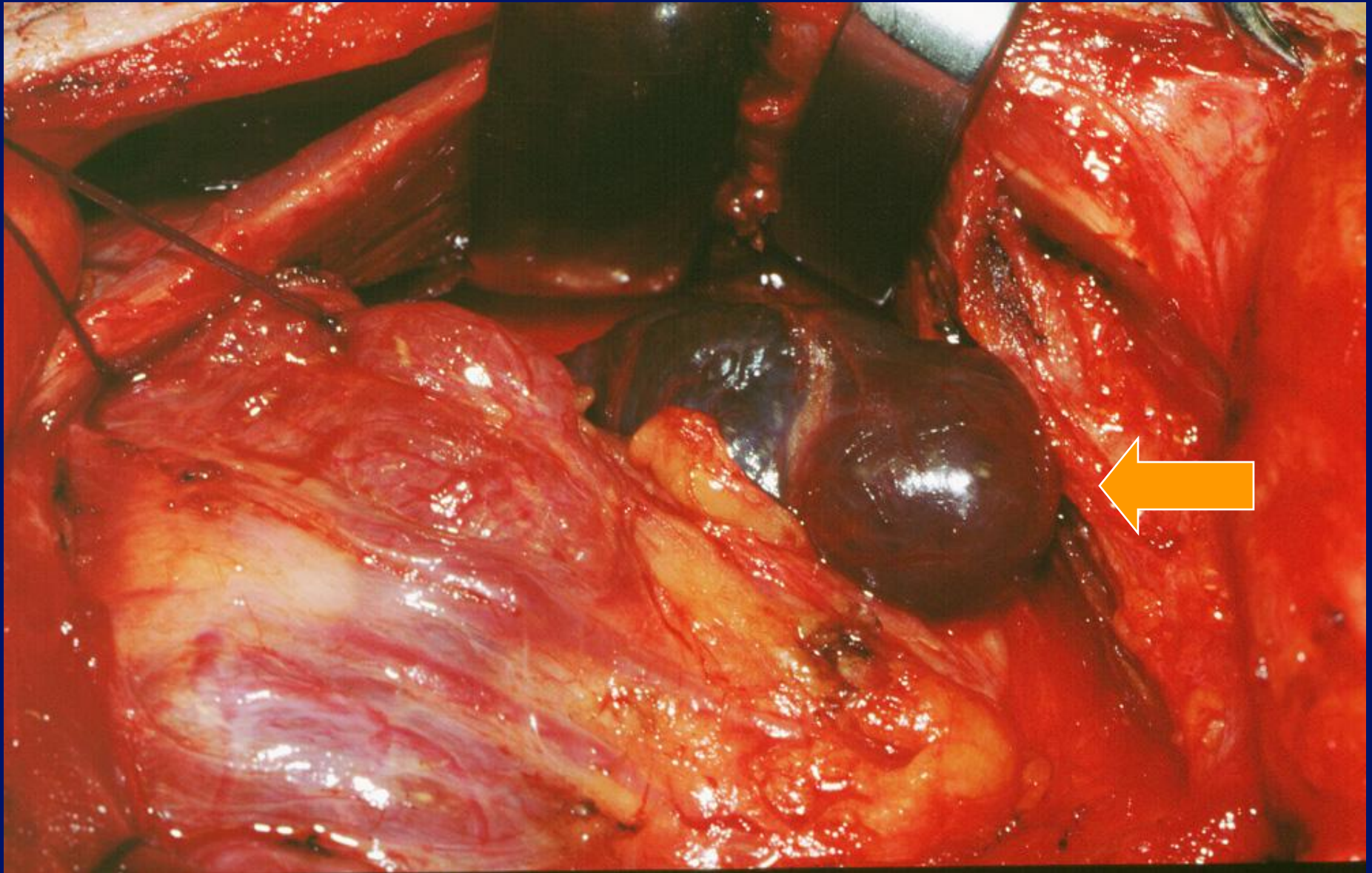


Neath experience.

- Pre –operative localisation positive.
- Reduction in operating time – 30%.
- 75 mins with good predictability.
- Reduction in stress levels.
- Planning.
- Failed localisation : range 75 – 225 mins

Neath experience.

- 31 cases.
- Ultrasound sensitivity – 72%
- (True positive – 62%; False positive – 14%; False negative – 24%)
- Ultrasound plus Sestamibi – sensitivity 88%



Morrison experience.

- 32 patients analysed.
- 22 patients had adenoma identified on US.
- 19 had proven adenoma(True positive)
- 3 – no adenoma –false positive.
- 2 – lymph nodes,1-thyroid nodule.

Results.

- 10/32 had negative US, 9 had adenoma proven (false neg), 1 had no adenoma identified at surgery.
- Ultrasound – Sens : 68%
PPV : 86%
NPV : 10%

Results

- Sestamibi scans on all US negative.(2 US positive)
- 12 patients : 7 positive-all proven (Tp)
- : 5 negative (4 proven (F-ve))
- : (1 disease negative.)
- Ultrasound plus Sestamibi – Sensitivity 70%.

Comparison?

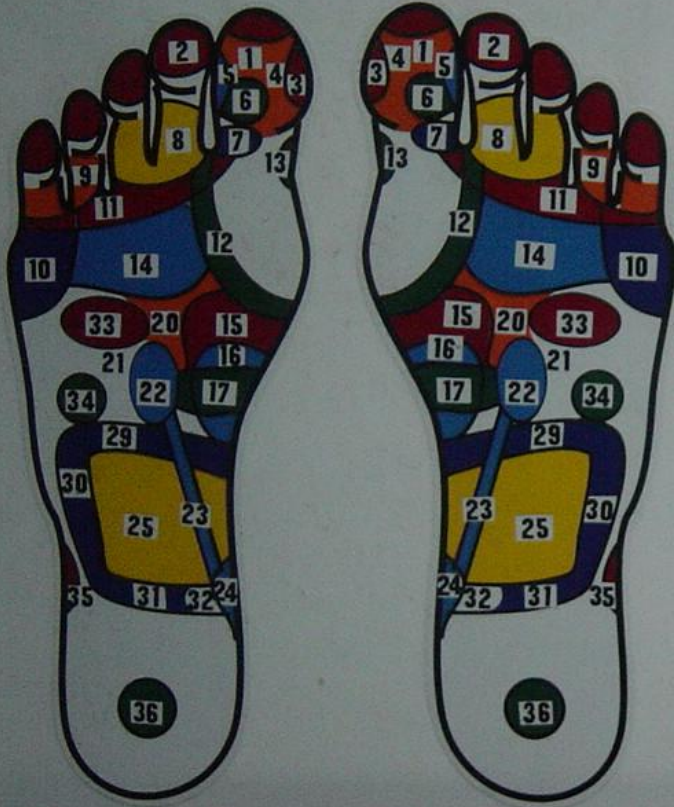
- WJS review.
- 52 studies reviewed.
- Sens range from 39% to 90%.
- Highlights side /site differences in interpretation.

Accuracy.

- Side : 88% (left /right)
- Site : 81% (superior/inferior)

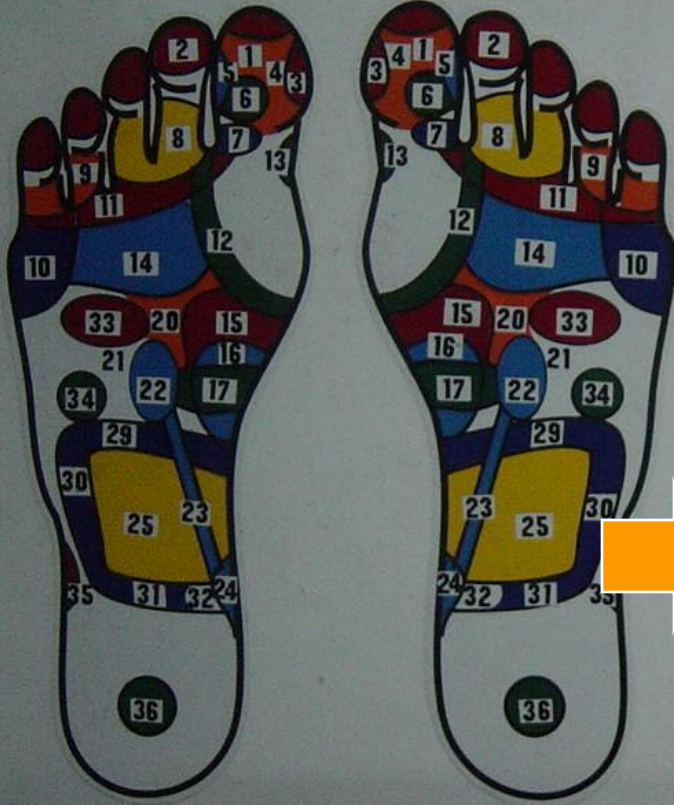


FOOT MASSAGE



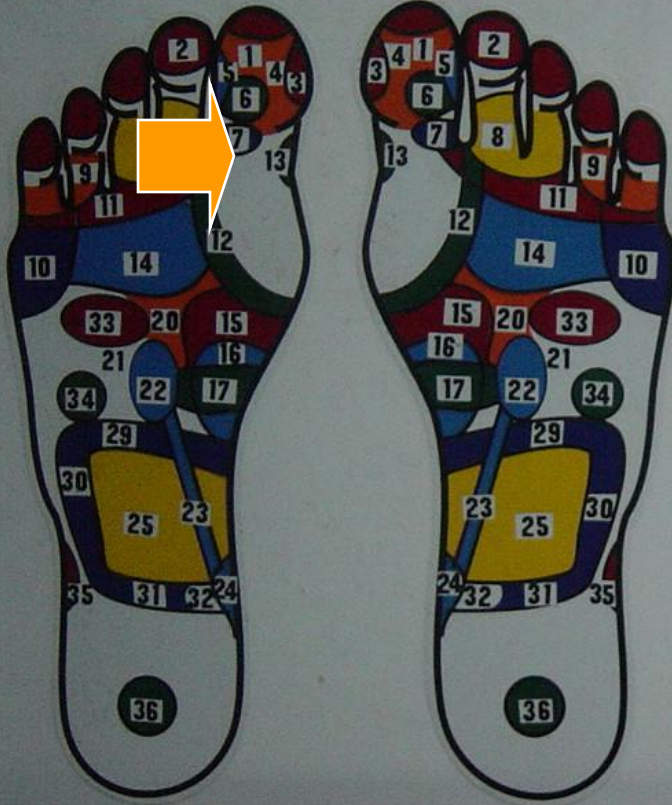
- | | | | |
|----|-----------------|----|------------------|
| 2 | FRONTAL | 20 | SOLAR PLEXUS |
| 3 | CEREBELLUM | 21 | ADRENAL GLANDS |
| 4 | PITUITARY GLAND | 22 | KIDNEYS |
| 5 | TEMPORAL AREA | 23 | URETER |
| 6 | NOSE | 24 | BLADDER |
| 7 | NECK | 25 | SMALL INTESTINES |
| 8 | EYE | 26 | APPENDIX |
| 9 | EAR | 28 | ASCENDING COLON |
| 11 | TRAPEZOID | 29 | TRANSVERSE COLON |
| 12 | THYROID GLANDS | 30 | DESCENDING COLON |
| 13 | PARATHYROID | 31 | RECTUM |
| 14 | LUNGS | 32 | ANUS |
| 15 | STOMACH | 33 | HEART |
| 16 | DUODENUM | 34 | SPLEEN |
| 18 | LIVER | 35 | GENITAL GLANDS |
| 19 | GALL BLADDER | 1 | HEAD |

FOOT MASSAGE




- | | | | |
|----|-----------------|----|------------------|
| 2 | FRONTAL | 20 | SOLAR PLEXUS |
| 3 | CEREBELLUM | 21 | ADRENAL GLANDS |
| 4 | PITUITARY GLAND | 22 | KIDNEYS |
| 5 | TEMPORAL AREA | 23 | URETER |
| 6 | NOSE | 24 | BLADDER |
| 7 | NECK | 25 | SMALL INTESTINES |
| 8 | EYE | 26 | APPENDIX |
| 9 | EAR | 28 | ASCENDING COLON |
| 11 | TRAPEZOID | 29 | TRANSVERSE COLON |
| 12 | THYROID GLANDS | 30 | DESCENDING COLON |
| 13 | PARATHYROID | 31 | RECTUM |
| 14 | LUNGS | 32 | ANUS |
| 15 | STOMACH | 33 | HEART |
| 16 | DUODENUM | 34 | SPLEEN |
| 18 | LIVER | 35 | GENITAL GLANDS |
| 19 | GALL BLADDER | 1 | HEAD |

FOOT MASSAGE



- | | | | |
|----|-----------------|----|------------------|
| 2 | FRONTAL | 20 | SOLAR PLEXUS |
| 3 | CEREBELLUM | 21 | ADRENAL GLANDS |
| 4 | PITUITARY GLAND | 22 | KIDNEYS |
| 5 | TEMPORAL AREA | 23 | URETER |
| 6 | NOSE | 24 | BLADDER |
| 7 | NECK | 25 | SMALL INTESTINES |
| 8 | EYE | 26 | APPENDIX |
| 9 | EAR | 28 | ASCENDING COLON |
| 11 | TRAPEZOID | 29 | TRANSVERSE COLON |
| 12 | THYROID GLANDS | 30 | DESCENDING COLON |
| 13 | PARATHYROID | 31 | RECTUM |
| 14 | LUNGS | 32 | ANUS |
| 15 | STOMACH | 33 | HEART |
| 16 | DUODENUM | 34 | SPLEEN |
| 18 | LIVER | 35 | GENITAL GLANDS |
| 19 | GALL BLADDER | 1 | HEAD |



www.headandneckultrasound.co.uk

© www.aberystwyth.org.uk

www.headandneckultrasound.co.uk